



# Challenging cases

Dr. Tarek Abdelsamie, FRCS MD  
Cornea and Refractive Surg consultant  
MIOR 2019



# CASE 1

**MIOR 2019**

**1-3 OCTOBER 2019** | MEMORIAL INSTITUTE FOR OPHTHALMIC RESEARCH

## Case #1

- 55 American patient
- Works at the USA embassy
- Seeking refractive surgery
- Saw many doctors

**MIOR 2019**

**1-3  
OCTOBER  
2019**

MEMORIAL INSTITUTE FOR  
OPHTHALMIC RESEARCH

## Case #1

- VAsc: 1.0 each eye
- MR:

OD: PLANO	1.0
OS: PLANO / - 0.5 X 25	1.0
- Near add + 1.5 OU
- Cycloplegic refraction: the same

**MIOR 2019**

**1-3  
OCTOBER  
2019**

MEMORIAL INSTITUTE FOR  
OPHTHALMIC RESEARCH

# Case #1

- She does not want to get rid of reading glasses !!!!!

## Tennis

Cannot see the ball properly when it comes close

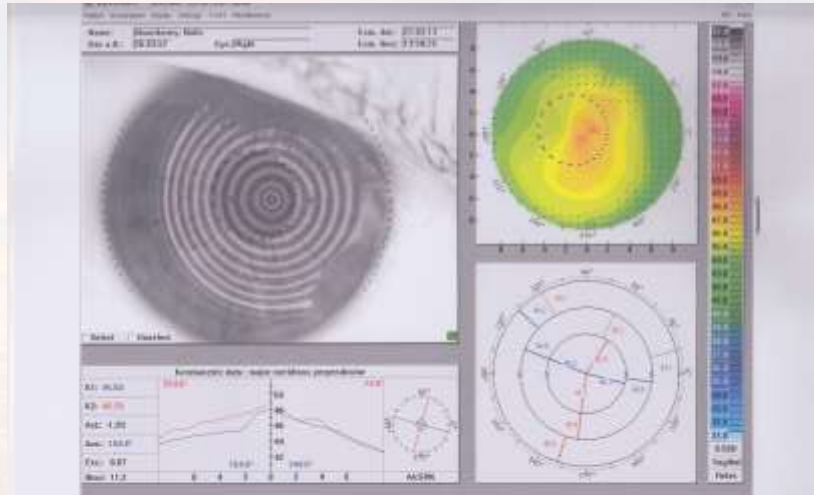
MIOR 2019

1-3  
OCTOBER  
2019

MEMORIAL INSTITUTE FOR  
OPHTHALMIC RESEARCH

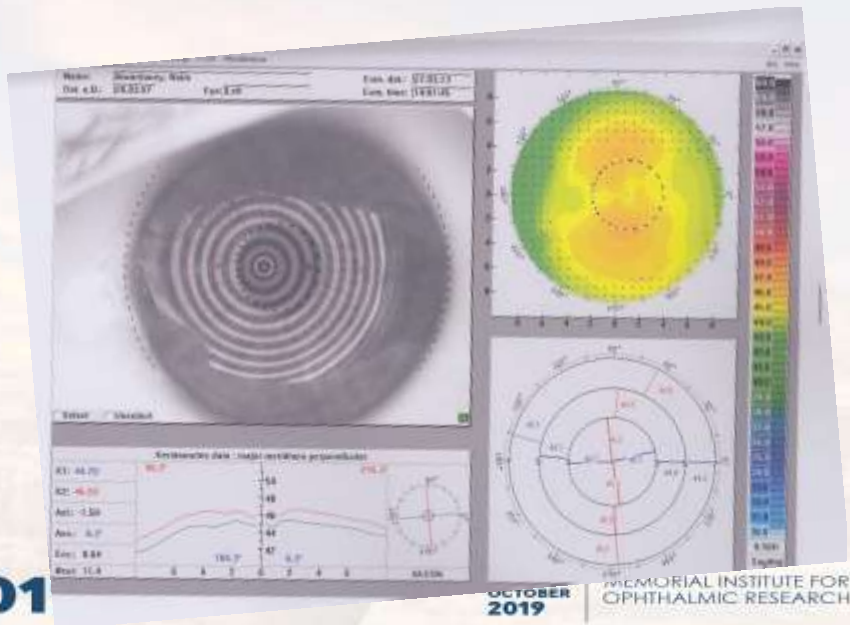
# Case #1

Pachy 521



# Case #1

Pachy 534



# Case #1

What should I do now??



MIOR 2019

1-3  
OCTOBER  
2019

MEMORIAL INSTITUTE FOR  
OPHTHALMIC RESEARCH

## Case #1

- Leave her alone
- PresbyLASIK
- Monovision

**MIOR 2019**

**1-3  
OCTOBER  
2019**

MEMORIAL INSTITUTE FOR  
OPHTHALMIC RESEARCH

## Case #1

**Monovision**

**MIOR 2019**

**1-3  
OCTOBER  
2019**

MEMORIAL INSTITUTE FOR  
OPHTHALMIC RESEARCH



## Case #1

eyeare

MEMORIAL INSTITUTE FOR OPHTHALMIC RESEARCH

LASIK SHEET

Name: Dr. Mohamed Elmaghrabi  
 Age: 35 Sex: M  
 Refractive Error: -1.00

ID: 10000000000000000000 Ref exam date: 10/15/19

Pre-operative data	
LEIK	OK
Monocular refraction	OD: -1.00 DS
BCVA	OD: 20/20
ETV	MS-J, R, 0
ETD	MS-J, R, 0
Posteriority	SD

Operative data	
Type of laser	OK
Surgeon	Dr. Mohamed Elmaghrabi
Target	-1.00 DS
Flap thickness	160 microns
Initial correction	-1.00 DS
Final correction	-1.00 DS
Stitch	3/1

Follow-up	
DATE	OK
1	OK
2	OK
3	OK
4	OK
5	OK
6	OK
7	OK
8	OK
9	OK
10	OK

MIOR 2019

MEMORIAL INSTITUTE FOR  
OPHTHALMIC RESEARCH

## Case #1

- CL trial
- Not less than 3 weeks
- Non dominant eye for reading

MIOR 2019

1-3  
OCTOBER  
2019MEMORIAL INSTITUTE FOR  
OPHTHALMIC RESEARCH



# CASE 2

**MIOR 2019**

**1-3 OCTOBER 2019** | MEMORIAL INSTITUTE FOR OPHTHALMIC RESEARCH



## Case #2

- 24 female Saudi patient
- Seeking refractive surgery
- Travelling in few days



**MIOR 2019**

**1-3 OCTOBER 2019** | MEMORIAL INSTITUTE FOR OPHTHALMIC RESEARCH

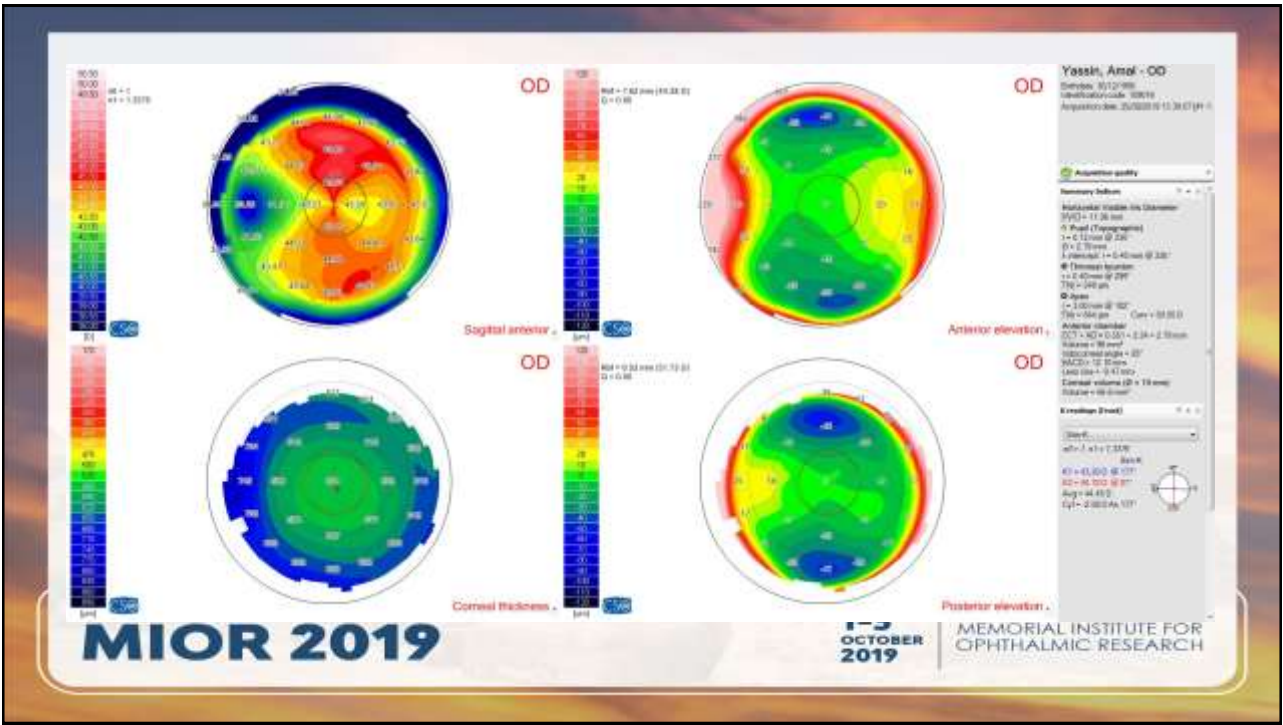
# Case #2

- Vasc: CF OU
- MR:
  - OD -10.0 -2.5 x 175
  - OS -11.75 -3.75 x 170
- VAcc: 0.8 OU

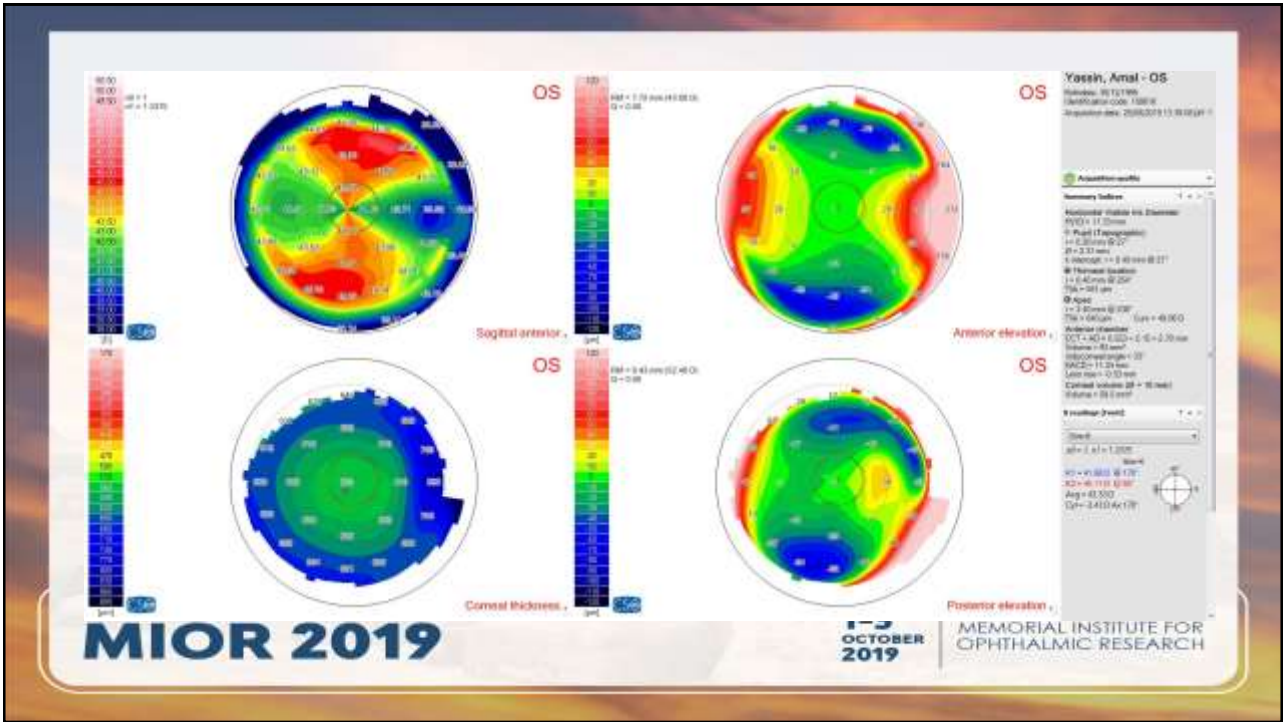
**MIOR 2019**

**1-3  
OCTOBER  
2019**

MEMORIAL INSTITUTE FOR  
OPHTHALMIC RESEARCH







# Case #2

What should I do now??

**MIOR 2019**

**1-3 OCTOBER 2019**

**MEMORIAL INSTITUTE FOR OPHTHALMIC RESEARCH**

## Case #2

- LASIK / FEMTOLASIK
- Toric ICL
- Bioptics

**MIOR 2019**

**1-3  
OCTOBER  
2019**

MEMORIAL INSTITUTE FOR  
OPHTHALMIC RESEARCH

## Case #2

**Bioptics**

Saves time and money

**MIOR 2019**

**1-3  
OCTOBER  
2019**

MEMORIAL INSTITUTE FOR  
OPHTHALMIC RESEARCH

## Case #2

- Do the flap 1<sup>st</sup>
- ICL
- Ablation

**MIOR 2019**

**1-3  
OCTOBER  
2019**

MEMORIAL INSTITUTE FOR  
OPHTHALMIC RESEARCH

## CASE 3

**MIOR 2019**

**1-3  
OCTOBER  
2019**

MEMORIAL INSTITUTE FOR  
OPHTHALMIC RESEARCH

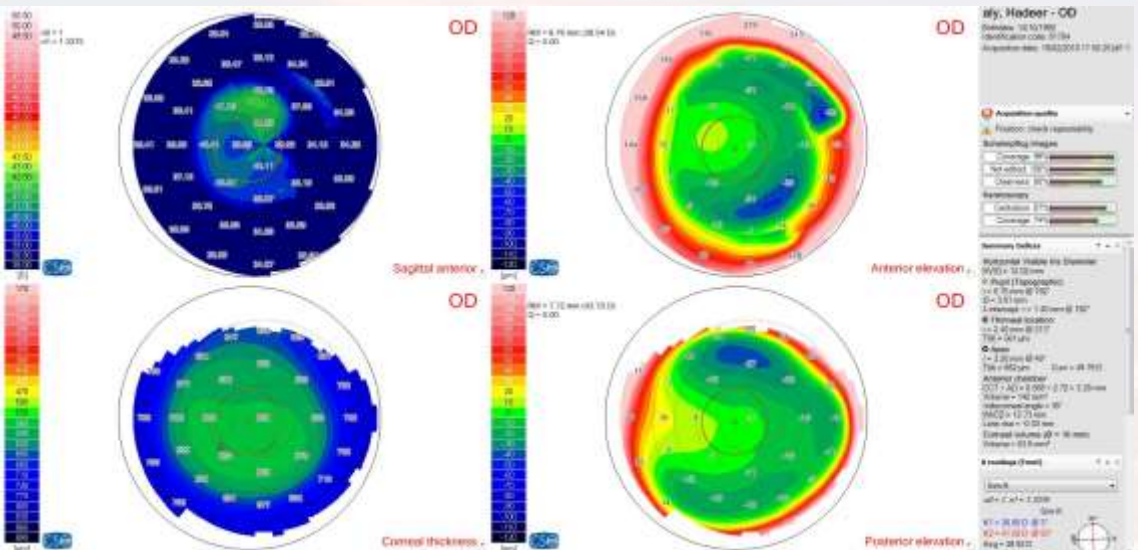
# Case #3

- 27 female
- Seeking refractive surgery
- VAsc:
  - OD 0.05
  - OS 0.1

**MIOR 2019**

**1-3  
OCTOBER  
2019**

MEMORIAL INSTITUTE FOR  
OPHTHALMIC RESEARCH

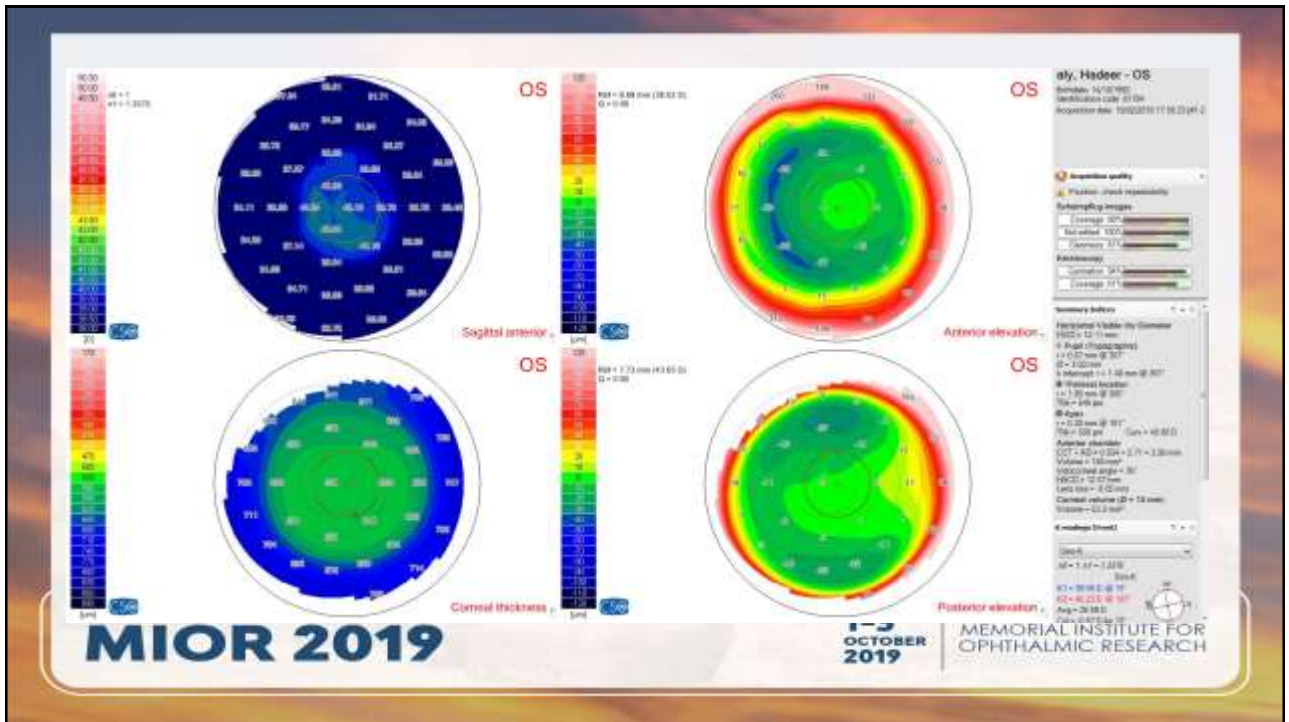


**MIOR 2019**

**1-3  
OCTOBER  
2019**

MEMORIAL INSTITUTE FOR  
OPHTHALMIC RESEARCH





## Case #3

- MR
  - OD +5.0 – 1.0 x 155
  - OS + 4.0 sph
- Cyclo Ref
  - OD + 6.0 – 1.25 x 158
  - OS + 5.0 – 0.25 x 37

**MIOR 2019**

**1-3  
OCTOBER  
2019**

MEMORIAL INSTITUTE FOR  
OPHTHALMIC RESEARCH





# CASE 4

**MIOR 2019**

**1-3  
OCTOBER  
2019** | MEMORIAL INSTITUTE FOR  
OPHTHALMIC RESEARCH



## Case #4

- PKP OS Jan 2010
- Femto AK Jan 2017
- BCVA is not satisfying
- Seeking Refractive surgery

**MIOR 2019**

**1-3  
OCTOBER  
2019** | MEMORIAL INSTITUTE FOR  
OPHTHALMIC RESEARCH

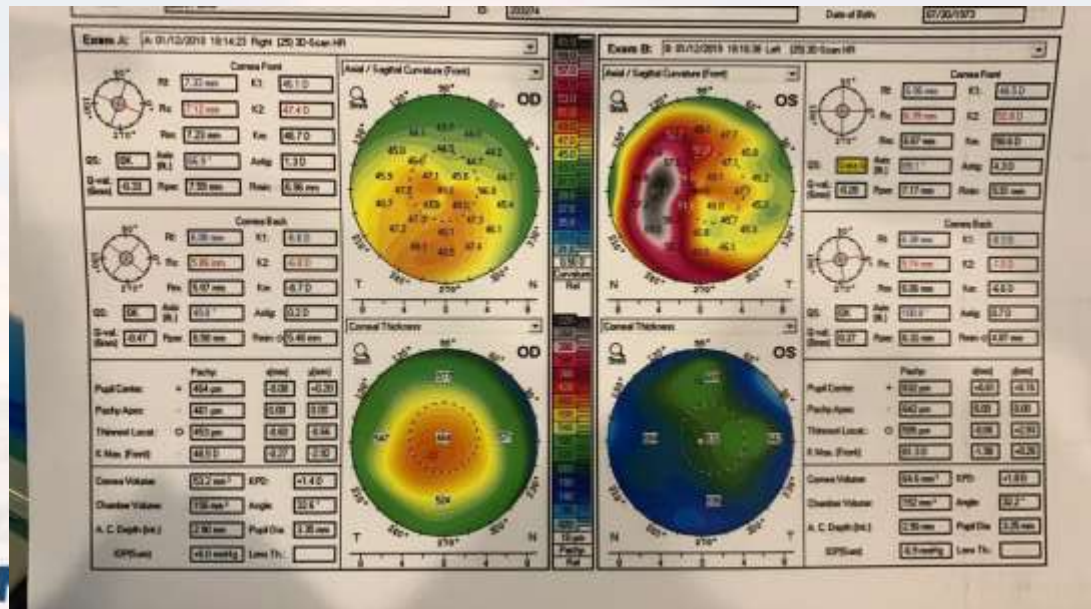
# Case #4

- Autorefr:
  - OD -1.5 -1.5 x 85
  - OS -4.5 -1.0 x 56
- MR
  - OD -2.0 -1.5 x 85     0.7
  - OS -1.5 -1.0 x 55     0.3

**MIOR 2019**

**1-3  
OCTOBER  
2019**

MEMORIAL INSTITUTE FOR  
OPHTHALMIC RESEARCH



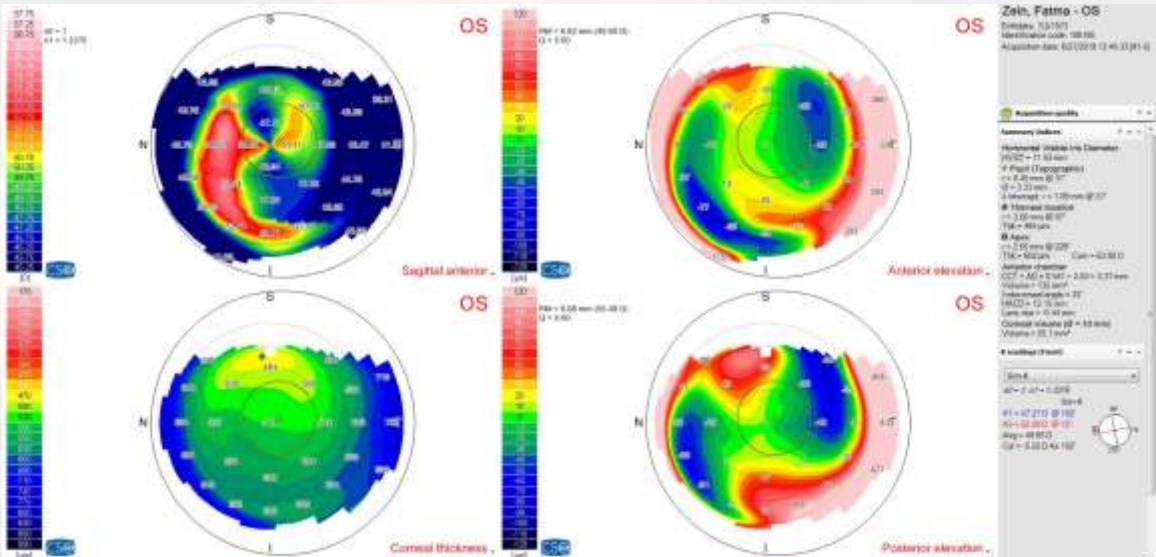
# Case #4

- Topo guided PTK
- MR OS -2.0 -5.0 x 100 0.6

**MIOR 2019**

**1-3  
OCTOBER  
2019**

MEMORIAL INSTITUTE FOR  
OPHTHALMIC RESEARCH



**MIOR 2019**

**OCTOBER  
2019**

OPHTHALMIC RESEARCH

## Case #4

- VAsc 0.05      VAcc 0.3
- Topo guided PRK
- LASIK 4 months later
- VAsc 0.6

**MIOR 2019**

**1-3  
OCTOBER  
2019**

MEMORIAL INSTITUTE FOR  
OPHTHALMIC RESEARCH

***THANK YOU***

**MIOR 2019**

**1-3  
OCTOBER  
2019**

MEMORIAL INSTITUTE FOR  
OPHTHALMIC RESEARCH