



Huge IOFB

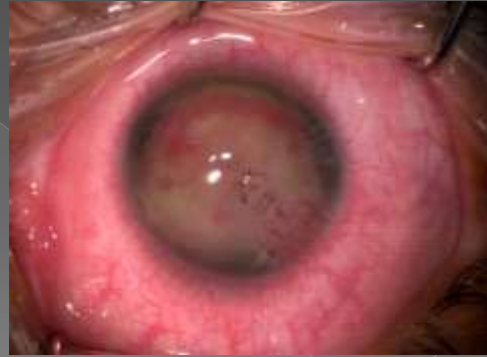**Mostafa Mahmoud Abousebei, Msc
MIOR**

Case 1

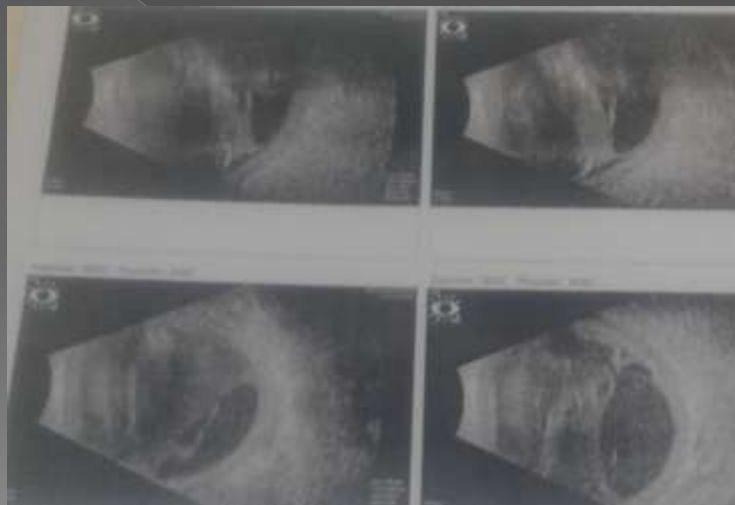
- 8 year old boy.
- FB entered the eye 1 month ago.
- Otherwise healthy.

Examination

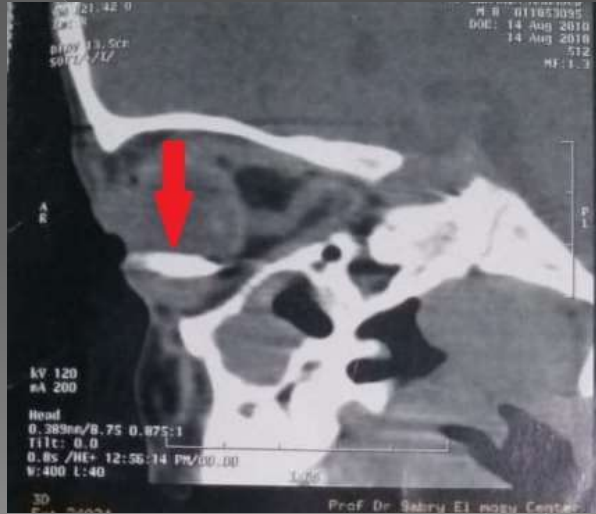- VA : LP
- Sutured corneal wound.
- Lens.
- Posterior segment.



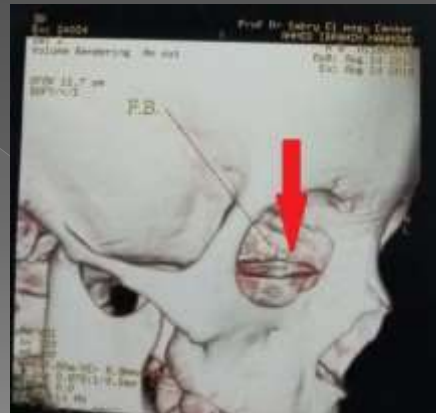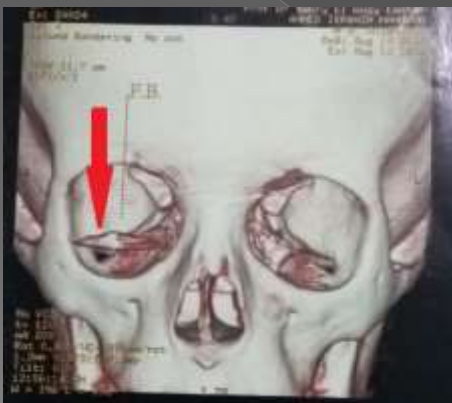B- scan



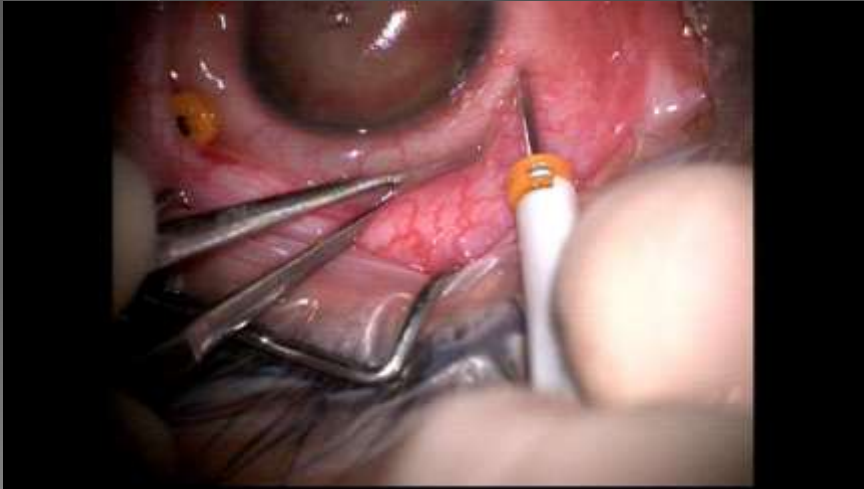Orbital CT



Orbital CT



Surgery



This IOFB was...

Zipper handle ☹ ☹



How was the trauma?

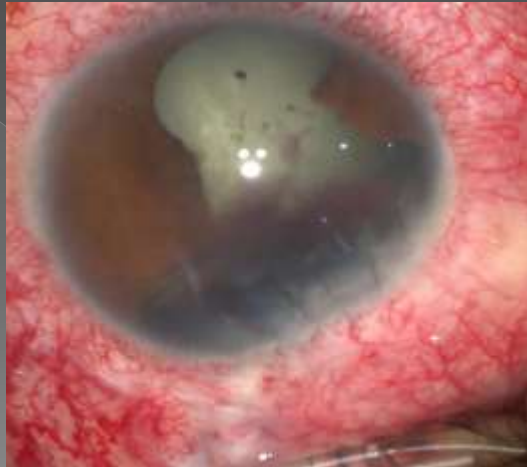

Case 2

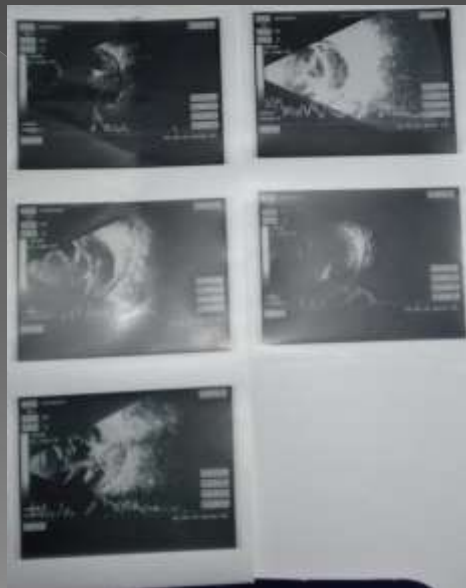- 27 years old male.
- Work as a carpenter.
- A metallic object entered his eye 10 days ago while working.

Examination

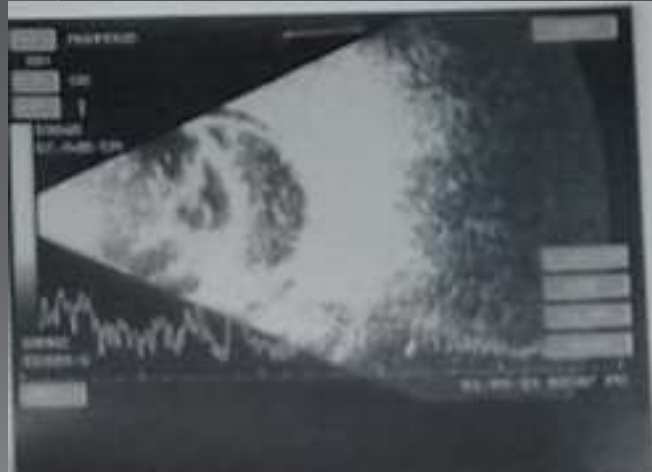- ◉ VA : HMBP
- ◉ Sutured limbal wound.
- ◉ Hyphema.
- ◉ Iris lacerations.
- ◉ Cataract.
- ◉ Low IOP.



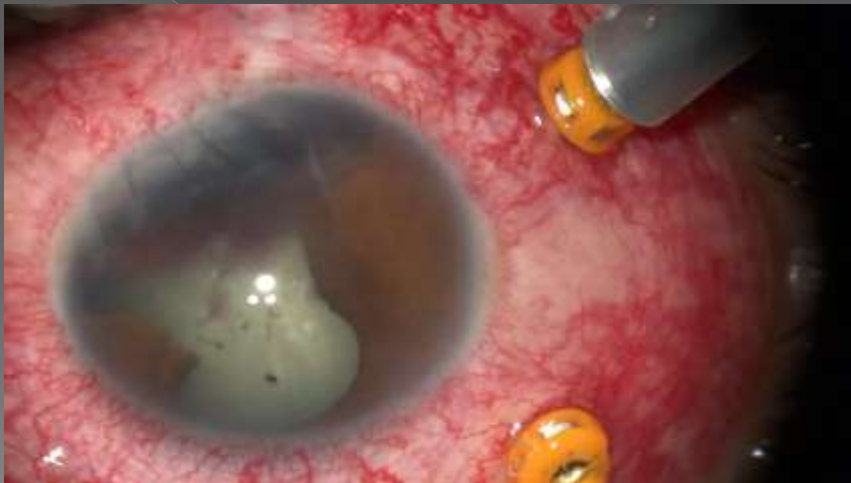B- scan




B- scan

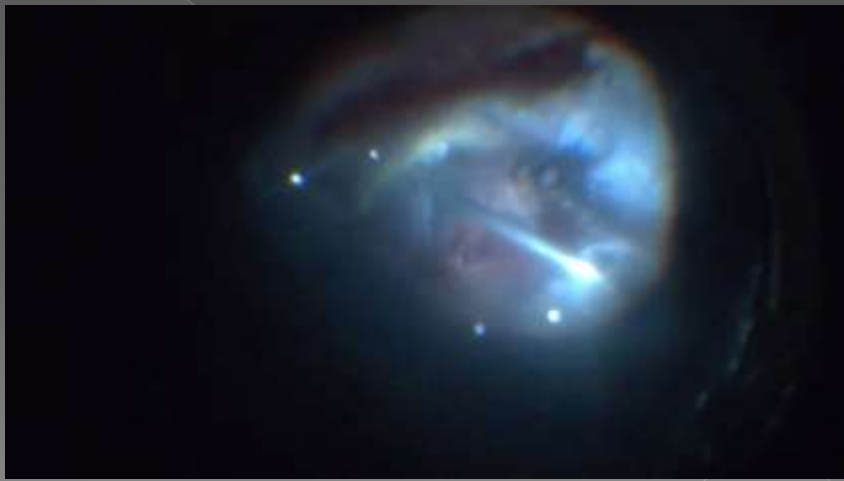

surgery






surgery



surgery



Take home message:

- ◉ When IOFB is suspected, consider preoperative CT orbit.
- ◉ Higher guages vitrectomy (25 & 27 G)would be less useful, so sometimes we should step back to lower guages instruments for better results.



Special thanks



**Prof. Dr.
Hazem Azab**



**Prof. Dr.
Hussam Omar**

Thank You