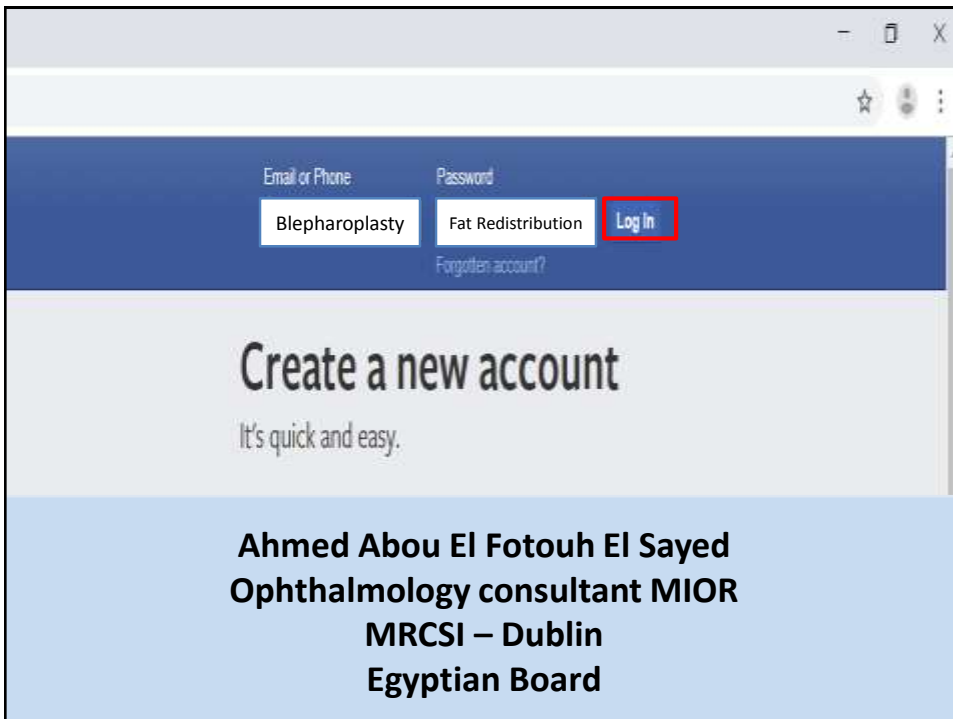
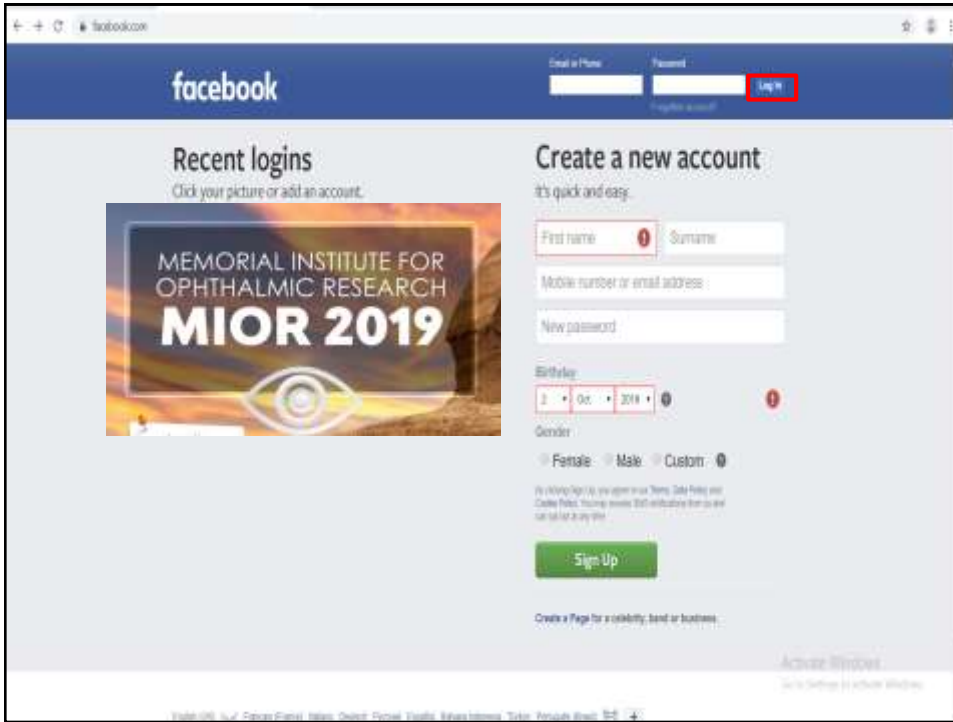
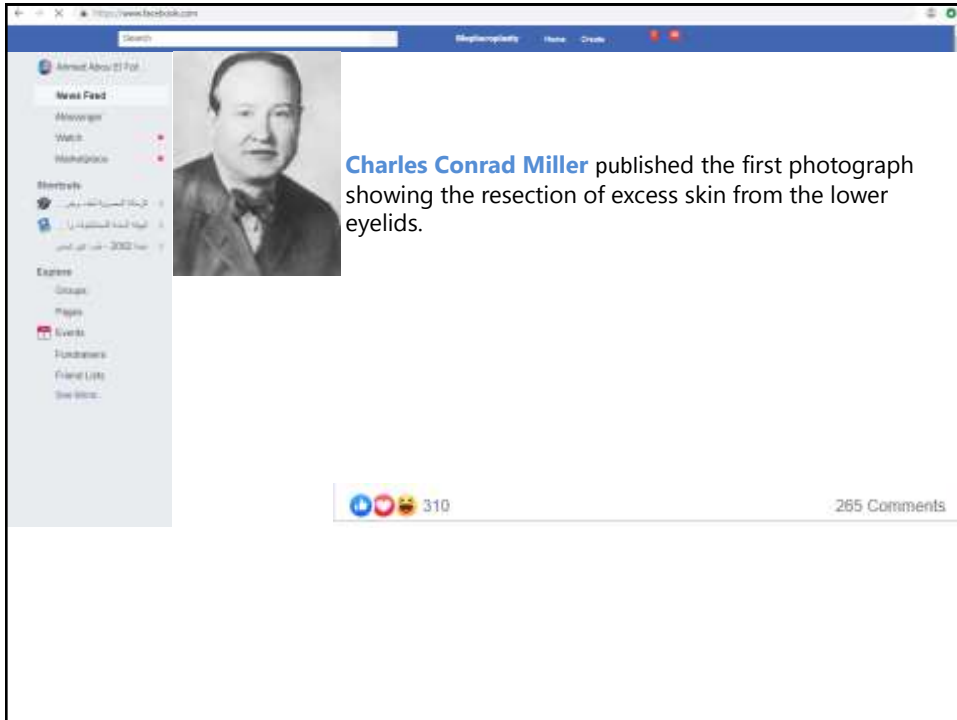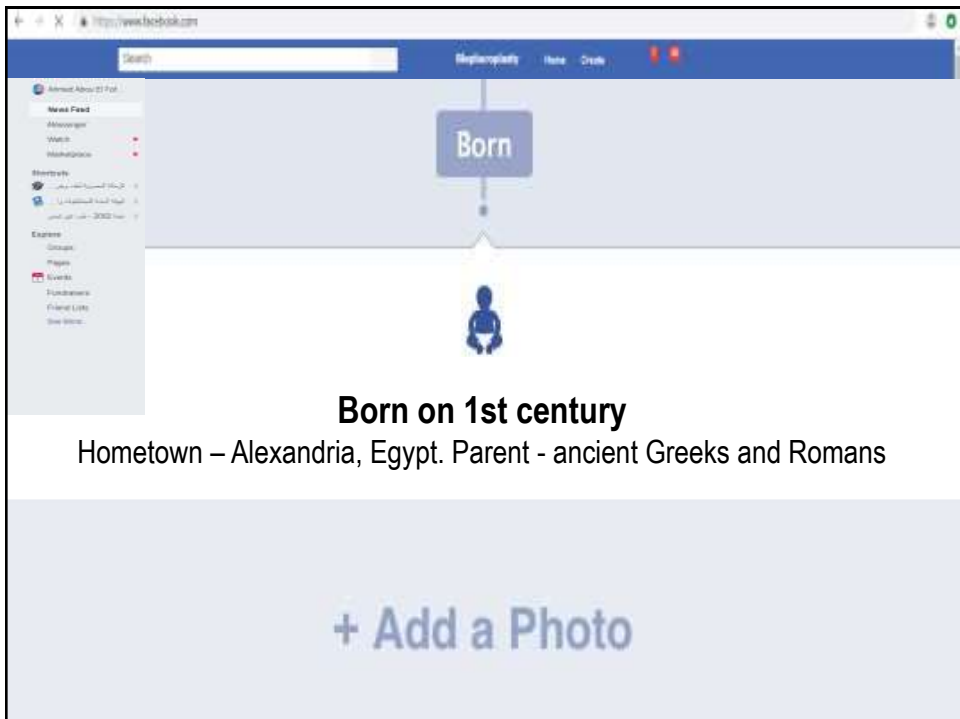
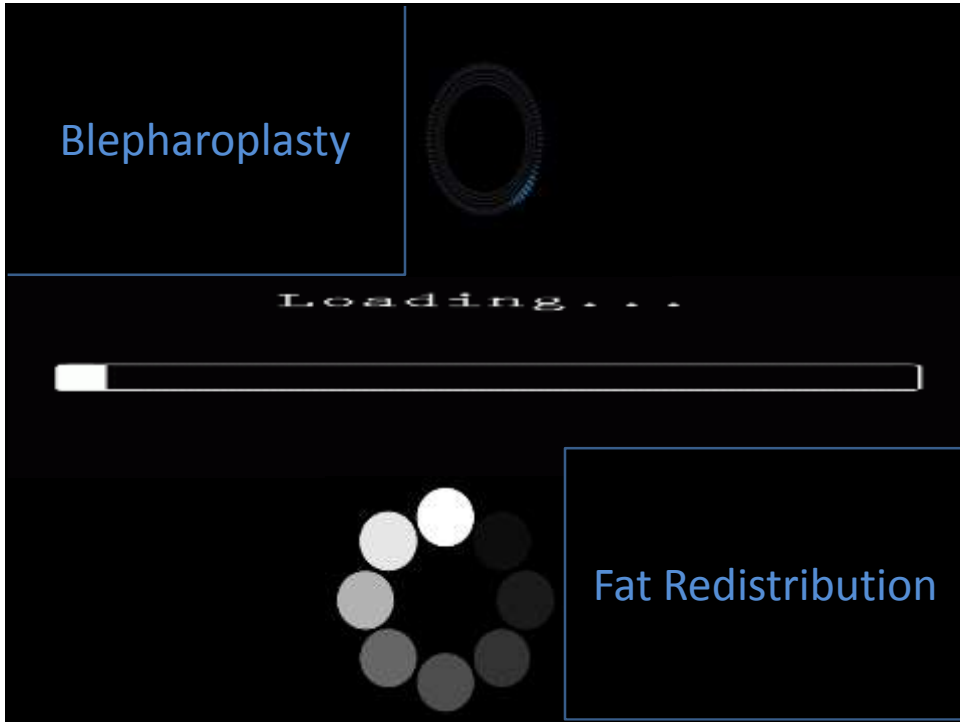Facebook post interface showing two posts about Aulus Cornelius Celsus.

**Aulus Cornelius Celsus**  
1st century  
Making an excision in the skin to relax the eyelids  
310 265 Comments

**Aulus Cornelius Celsus writing De Medicina**  
1st century  
310 265 Comments

Facebook post interface showing a post about Karl Ferdinand von Gräfe.

**Karl Ferdinand von Gräfe** coined the phrase blepharoplasty when the technique was used for repairing deformities caused by cancer in the eyelids in 1818  
310 265 Comments



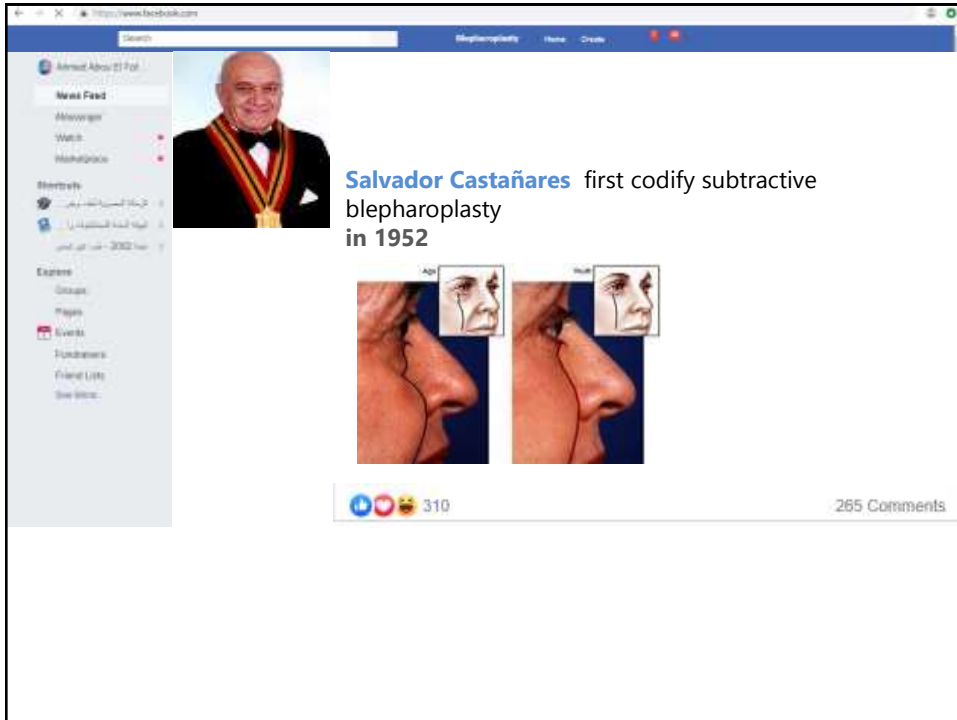
A screenshot of a Facebook post. The post is from a user named 'Ahmad Abou El Fakh'. The post content includes a black and white portrait of a man and a text overlay. The text overlay reads: 'Charles Conrad Miller published the first photograph showing the resection of excess skin from the lower eyelids.' Below the text, there are three reaction icons (like, love, wow) and the number '310'. At the bottom right of the post, it says '265 Comments'.

**Charles Conrad Miller** published the first photograph showing the resection of excess skin from the lower eyelids.



A screenshot of a Facebook post. The post is from a user named 'Ahmad Abou El Fakh'. The post content includes a black and white portrait of a man and a text overlay. The text overlay reads: 'Julien Bourguet first described a transconjunctival approach to the resection of herniated periorbital fat France in 1924'. Below the text, there are three reaction icons (like, love, wow) and the number '310'. At the bottom right of the post, it says '265 Comments'.

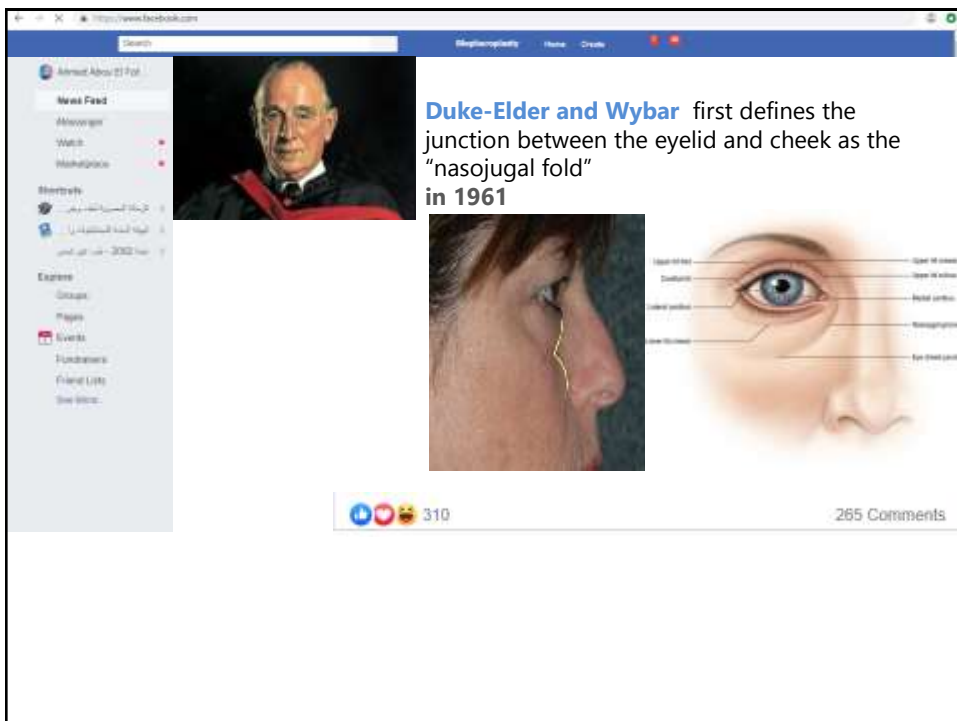
**Julien Bourguet** first described a transconjunctival approach to the resection of herniated periorbital fat France in 1924



A screenshot of a Facebook post from the page 'Blepharoplasty'. The post features a profile picture of Salvador Castañares, a man in a dark suit and a colorful sash. The text of the post reads: "Salvador Castañares first codify subtractive blepharoplasty in 1952". Below the text are two side-by-side photographs of a woman's face in profile, showing the eye area. The left photo is labeled 'After' and the right is labeled 'Before'. At the bottom of the post, there are reaction icons (like, love, wow) and the number '310', and on the right, it says '.265 Comments'.

Salvador Castañares first codify subtractive blepharoplasty in 1952

310 .265 Comments

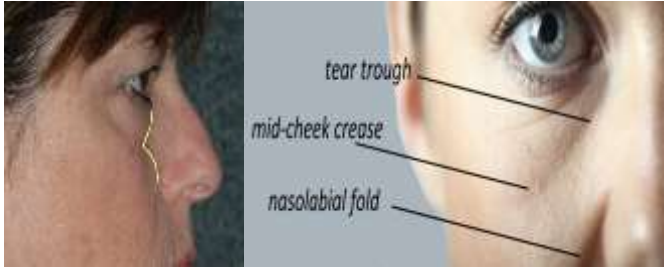


A screenshot of a Facebook post from the page 'Blepharoplasty'. The post features a profile picture of Duke-Elder and Wybar, two men in suits. The text of the post reads: "Duke-Elder and Wybar first defines the junction between the eyelid and cheek as the 'nasojugal fold' in 1961". Below the text is a photograph of a woman's face in profile, showing the eye area, with a yellow line tracing the nasojugal fold. To the right of the photo is a diagram of a human eye with various anatomical parts labeled: Upper lid fold, Lower lid fold, Ductus, Lateral canthus, Medial canthus, Nasojugal fold, Eye fold, and Eye fold junction. At the bottom of the post, there are reaction icons (like, love, wow) and the number '310', and on the right, it says '.265 Comments'.

Duke-Elder and Wybar first defines the junction between the eyelid and cheek as the "nasojugal fold" in 1961

310 .265 Comments



Flowers **Duke-Elder and Wybar** rename the same fold as "tear trough" in 1969



tear trough  
mid-cheek crease  
nasolabial fold

310 265 Comments

**Loeb** Lower blepharoplasty involving vascularized fat pads from the eyelid "sliding" into the cheek to fill the tear trough in 1981  
Federal University of São Paulo, Brazil

310 265 Comments

https://www.facebook.com

Search

English/Arabic Home Create

Ahmed Abu El Fadl

News Feed

Messages

Watch

Marketplace

Shortcuts

Groups


Pages

Events


Fundraisers

Friend Lists

See More...



**Kikkawa and two others** finished cadaveric dissection studies “orbitomalar ligament” in 1996



310

265 Comments

https://www.facebook.com

Search

English/Arabic Home Create

Ahmed Abu El Fadl

News Feed

Messages

Watch

Marketplace

Shortcuts

Groups


Pages

Events


Fundraisers

Friend Lists

See More...



**Hamra** “septal reset” technique in 2004

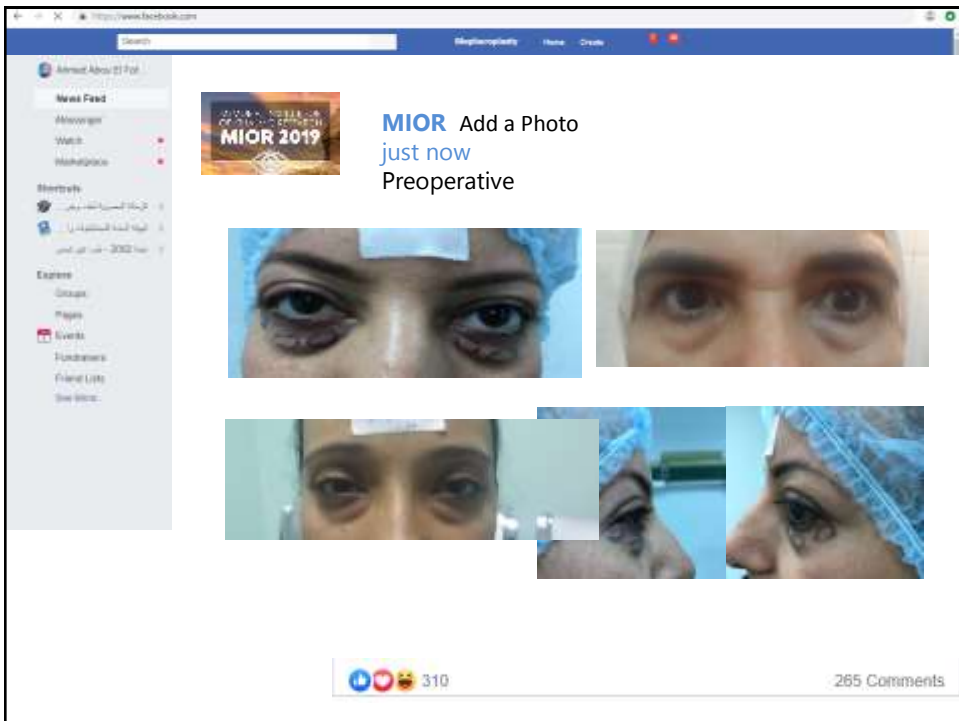


310

265 Comments



A screenshot of a Facebook post from the page 'Almad About El Fat'. The post features a profile picture of a man in a white lab coat. The main text of the post reads: 'Goldberg transconjunctival approach Fat repositioning 1998'. Below the text is a large graphic with the text 'Your Memories on Facebook' and 'we care about you and the memories you share here. We thought you'd like to look back on this post from 74 years ago.' To the left of the main text is a smaller profile picture of a man with a mustache. Below this is the text 'Transconjunctival approach Fat resection 1924'. At the bottom of the post, there are reaction icons (like, love, wow, haha) and the number '310', and on the right, it says '.265 Comments'.



A screenshot of a Facebook post from the page 'Almad About El Fat'. The post features a profile picture of a woman with a blue surgical cap. The main text of the post reads: 'MIOR Add a Photo just now Preoperative'. Below the text are four photographs showing a woman's eyes from different angles, likely preoperative views for a procedure. At the bottom of the post, there are reaction icons (like, love, wow, haha) and the number '310', and on the right, it says '.265 Comments'.



https://www.facebook.com

Search

English | Arabic | Home | Create

Amrout About El Pal

News Feed

Messages

Watch

Marketplace

Shortcuts

الجمهورية العربية السورية

الجمهورية العربية السورية

الجمهورية العربية السورية - 3000 likes

Explore

Groups


Pages


Events


Fundraisers

Friend Lists

See More...

 **MIOR** Shared a video just now  
Tranconjunctival approach



 310

265 Comments

https://www.facebook.com

Search

English | Arabic | Home | Create

Amrout About El Pal

News Feed

Messages

Watch

Marketplace

Shortcuts

الجمهورية العربية السورية

الجمهورية العربية السورية

الجمهورية العربية السورية - 3000 likes

Explore

Groups


Pages


Events


Fundraisers

Friend Lists

See More...

 **MIOR** Shared a video just now  
Transcutaneous approach



 310

265 Comments

A screenshot of a Facebook post from the user 'Ahmed Abu El Fal'. The post features a banner for 'MIOR 2019' (Middle East International Ocular Reconstructive Symposium) with the text 'MIOR Add a Photo just now Postoperative'. Below the banner are four close-up photographs of a woman's eyes, showing the results of a surgical procedure. The top-left photo shows the eyes before surgery, while the other three photos show the eyes after surgery, with visible improvements in eyelid position and eye appearance. At the bottom of the post, there are icons for likes, love, and wow, with a count of 310, and a comment count of 265.

A screenshot of a Facebook post from the user 'Ahmed Abu El Fal'. The post features a banner for 'MIOR 2019' with the text 'MIOR Add a Photo just now not without complications'. Below the banner are two close-up photographs of a woman's eyes. The top photo shows the eyes before surgery, and the bottom photo shows the eyes after surgery, with visible surgical scars and sutures around the eyes. At the bottom of the post, there are icons for likes, love, and wow, with a count of 310, and a comment count of 265.

Ahmed Abou El Fadl

News Feed

Messages

Watch

Marketplace

Shortcuts

Explore

Groups

Pages

Events

Fundraisers

Friend Lists

See More...

MIOR 2019

MIOR Add a Photo just now

2019

1955

310

265 Comments

Ahmed Abou El Fadl

News Feed

Messages

Watch

Marketplace

Shortcuts

Explore

Groups

Pages

Events

Fundraisers

Friend Lists

See More...

MIOR 2019

MIOR

Create Post

What's on your mind, Ahmed?

Photo/Video

Tag Friends

Feeling/Activ...

310

265 Comments

