

بِسْمِ اللَّهِ الرَّحْمَنِ الرَّحِيمِ

When a Non- Seeing eye matters!!

A New technique for Corneal Tattooing via intrastromal injection of liquid ink.

Dr. Nehal Omar Elfarouk



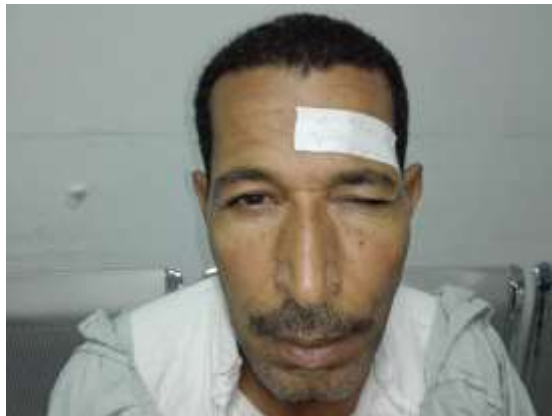

HOPELESS CASE



**BUT IT IS NOT ALWAYS
ABOUT VISION!!**

SOCIAL SHYNESS IS A BIG DEAL



BULLYING



CORNEAL TATTOO

Indications of corneal tattoo:

▶ Reconstructive cosmetic:

- ❖ Corneal opacities
- ❖ Leucocoria
- ❖ Corneal scars

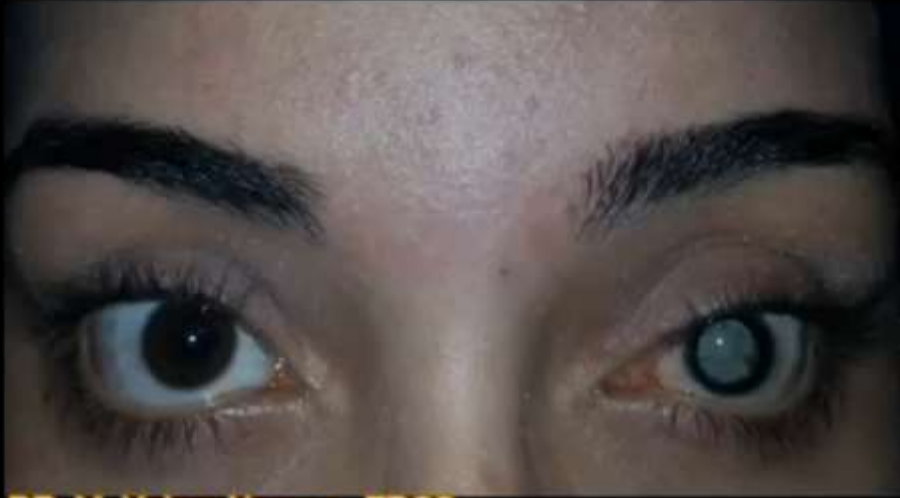▶ Optical (therapeutic):

- ❖ Albinism
- ❖ Aniridia
- ❖ Coloboma
- ❖ Iridodialysis
- ❖ Large PI

Techniques:

1. LASER ASSISTED TECHNIQUES:

Intralase Assisted Corneal Tattoo

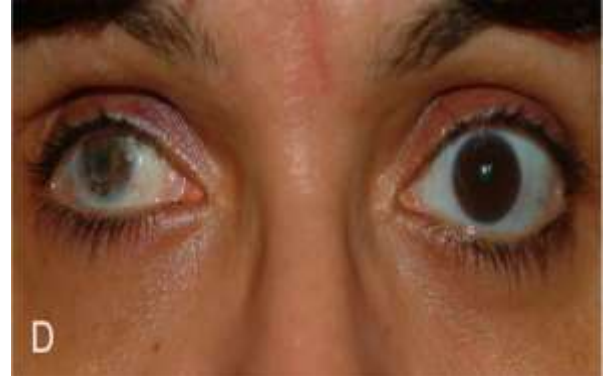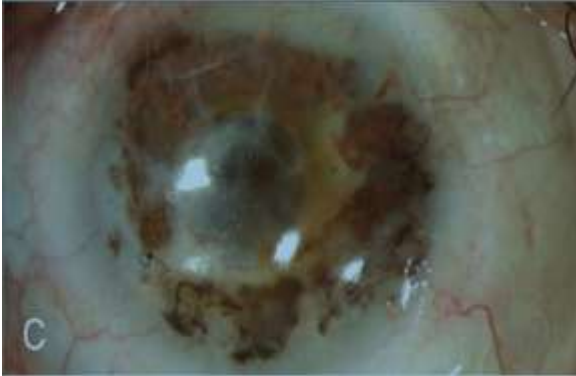


DR. M. Yahya Neama , FRCS
Almoosa General Hospital
Alahsa - KSA

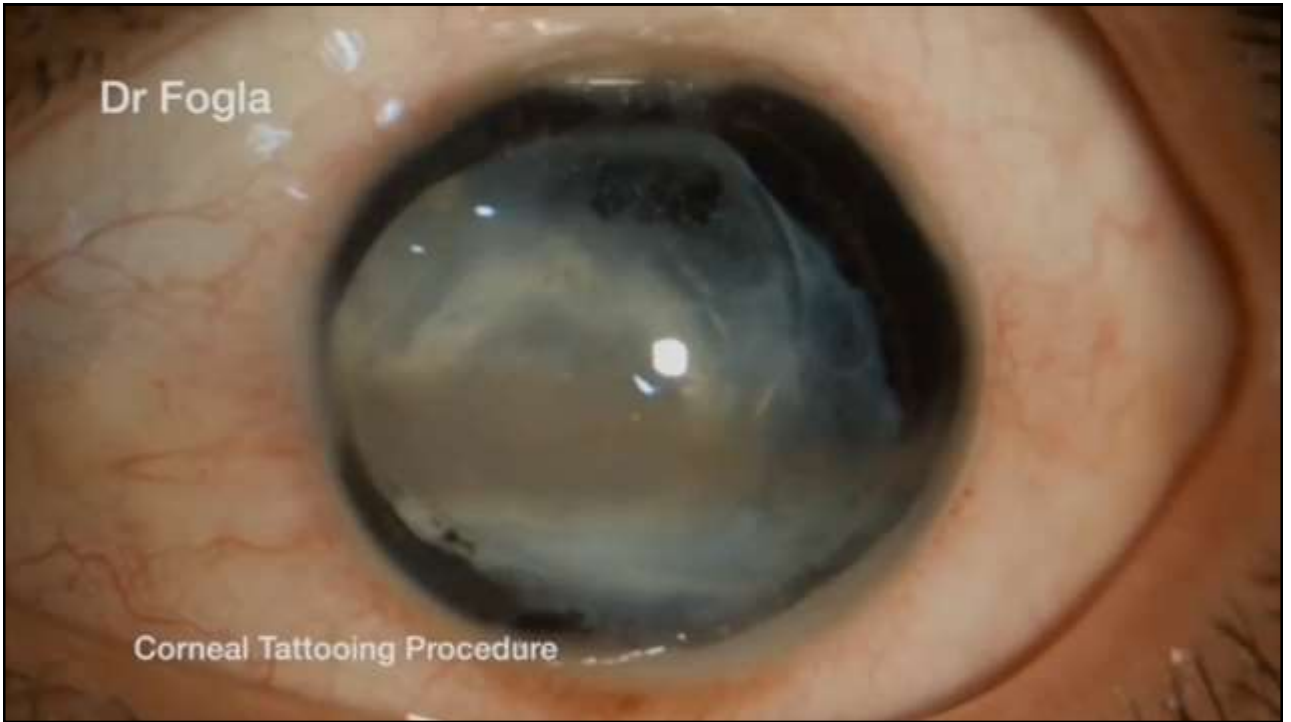Techniques:

**2. MANUAL
TECHNIQUES**

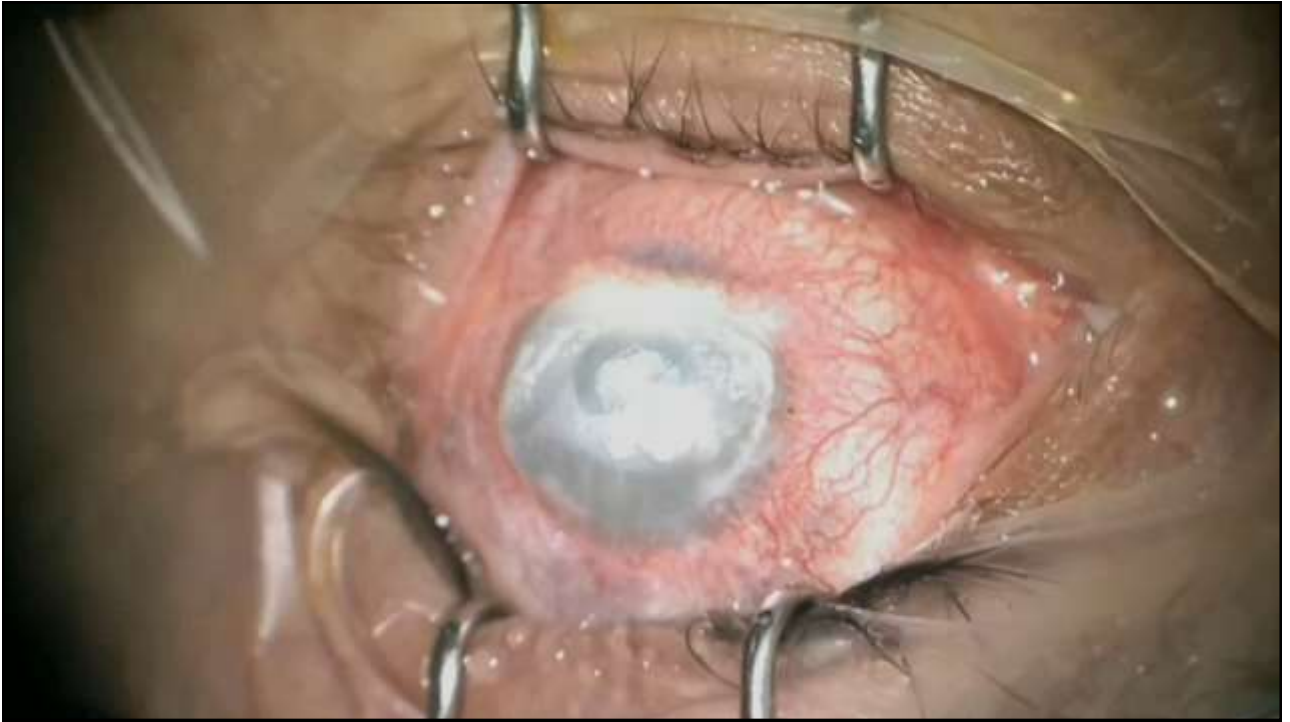Pointage Technique



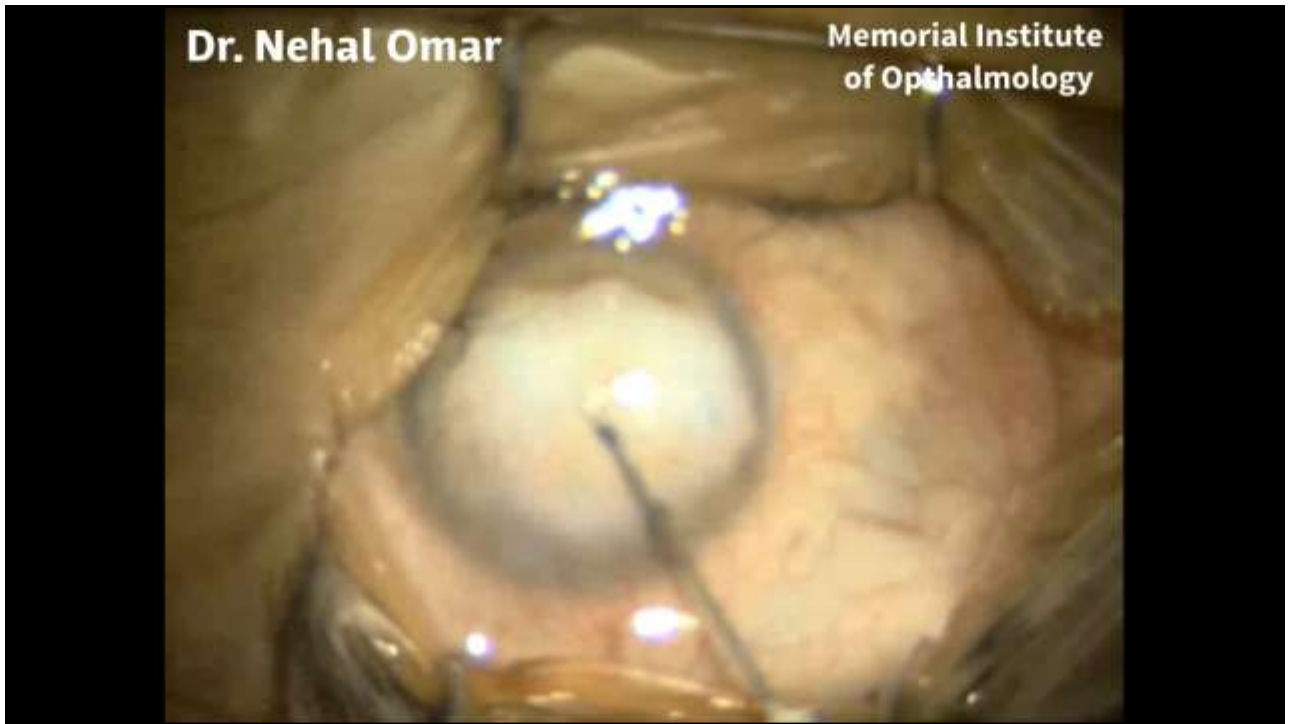
Manual flap construction



**Epithelial removal and
direct stromal stain**



INTRASTROMAL INJECTION



Intrastromal liquid ink Injection technique:

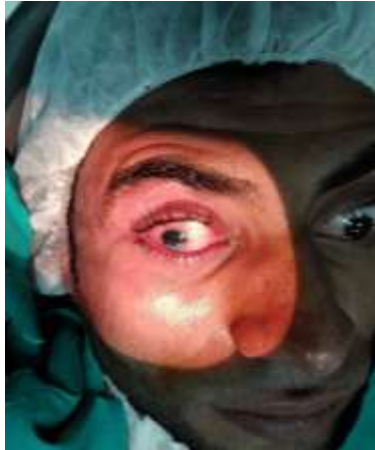- ▶ Intrastromal injection is a safe and effective technique for corneal tattooing as it can be done for opacities reaching the limbus and we can alter the depth of injection in each point in the cornea respecting the corneal pachymetry unlike the flap construction techniques either manual or femto assisted.
- ▶ In addition it is technically more rapid, easier and shows better homogeneous outcome in comparison to the puncture technique.

Results

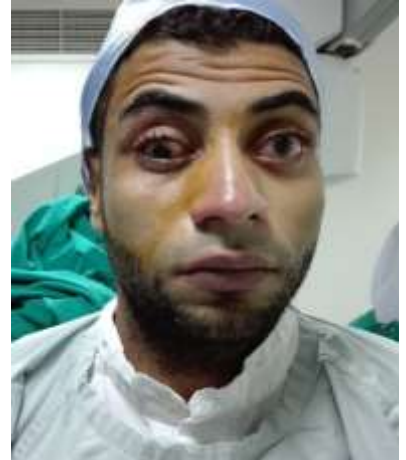First Session



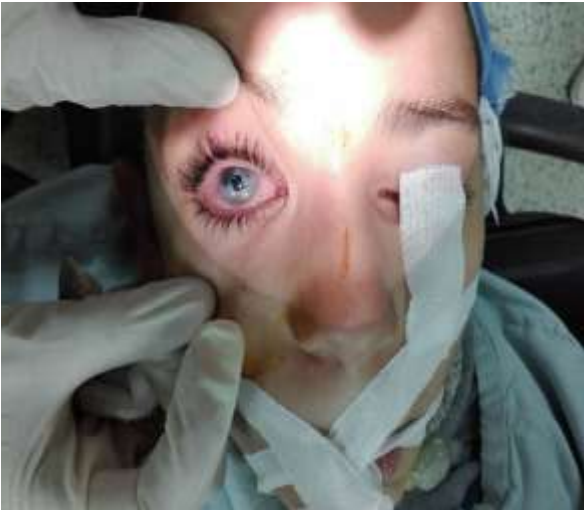Second Session



Third Session



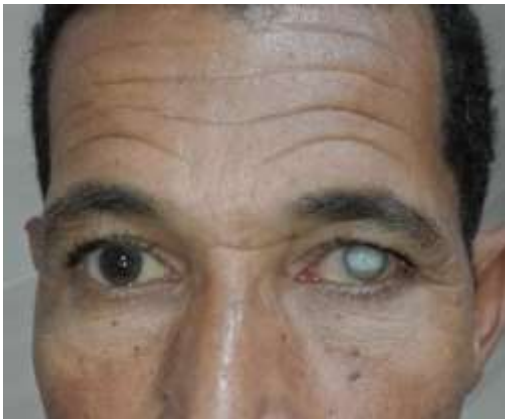First Session



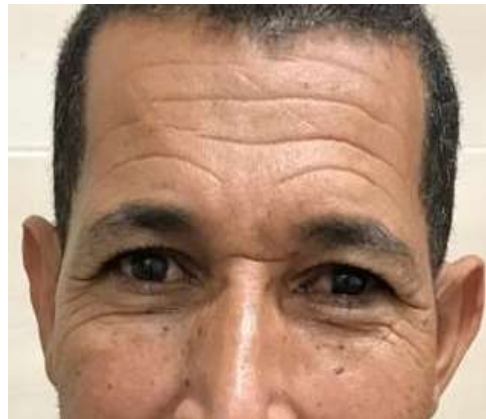Last Session



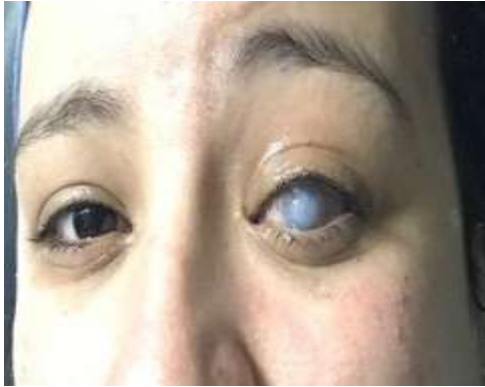Before



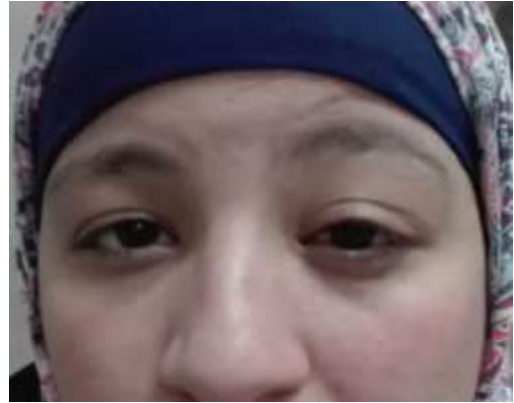After



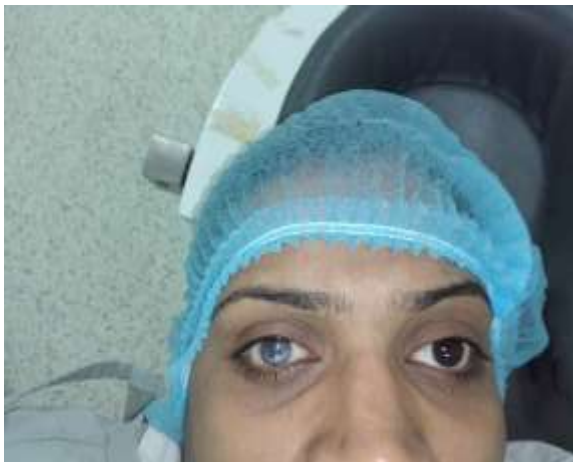Before



After



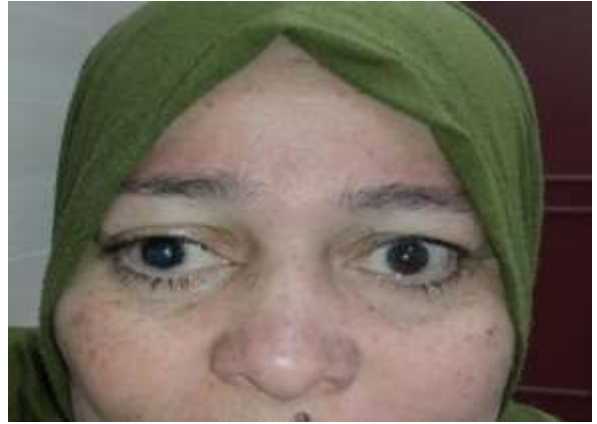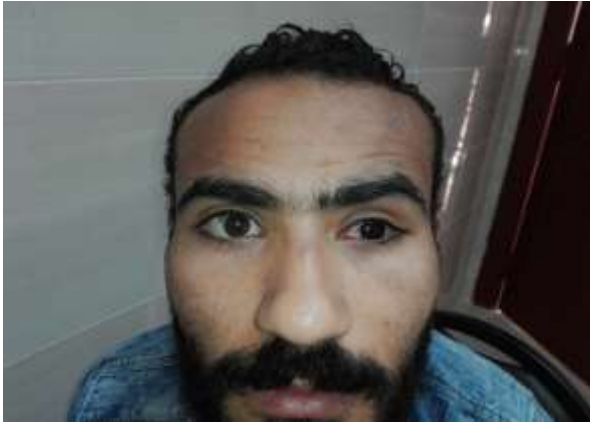
Before



After



Results



TAKE HOME MESSAGE

**Respect the patient's needs
as it is not always about
vision**

**“May Be A Non Seeing Eye
Could Matter”**





THANK YOU!