

The Giza Memorial Institute
for Ophthalmic Research (MIOR)

**When Anti-VEGF is an enemy
in Advanced PDR**

By
Tarek Badr El Din

FRCS , M.D.
Memorial Institute of Ophthalmology(MIOR)

Case

65 years old Male

G.H: IDDM since 9 years

C/O : Right diminution of vision

Dr. Tarek Badr - Report
Dr. Tarek Badr - Argon laser (one eye)

Air Puff : 13 | 14

UCVA : 0.1 | 0.3

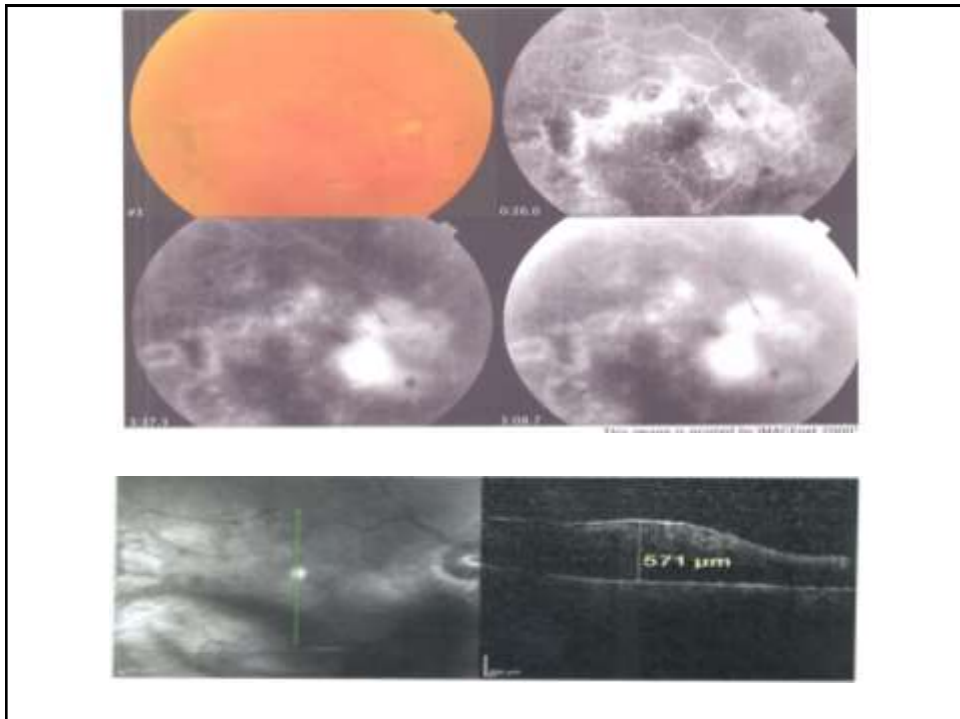
AR : Error / Error X * | +5.75 / -5.50 X 15°

Ant. : Pterygium

Lens : NC1 AC3 PSC1 | AC1

Post. : PDR + vit. fuge+ CME | Severe NPDR

Surgery Sheet :



Plan of Treatment

Either :

To do **Phaco & Anti-VEGF injection**

followed by PRP

or

To go directly for **Phaco-Vitrectomy**

Phaco & Anti-VEGF injection

followed a week by PRP

A Month later

Dr. Tarek Badr - Consultation

Air Puff : 13 | 16

AR : +1.50 / -2.50 X 120° | +4.75 / -1.75 X 15°

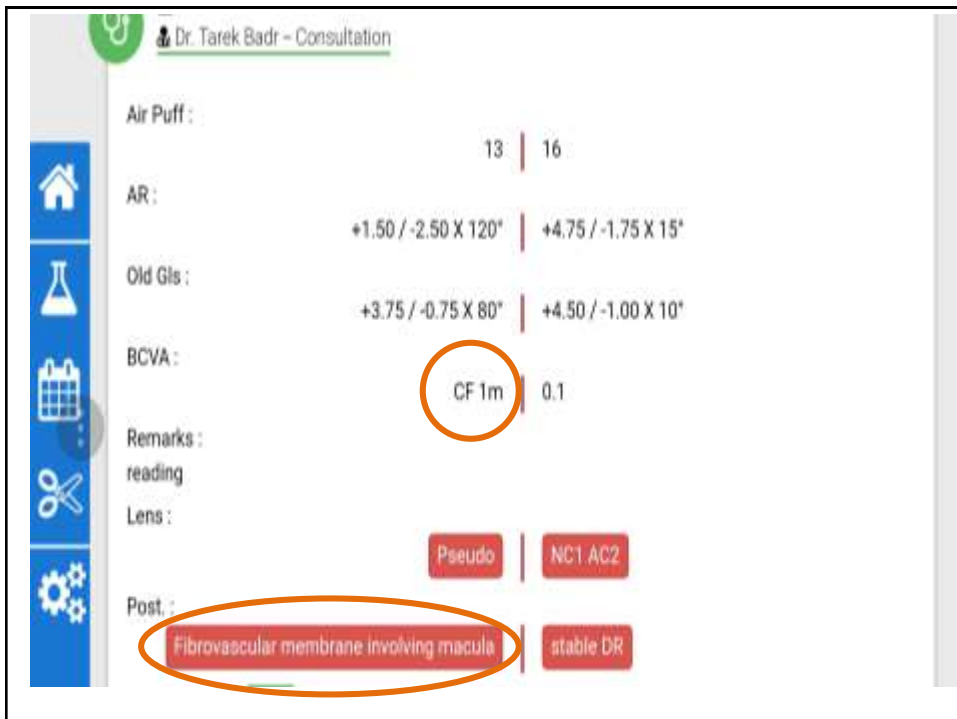
Old Gls : +3.75 / -0.75 X 80° | +4.50 / -1.00 X 10°

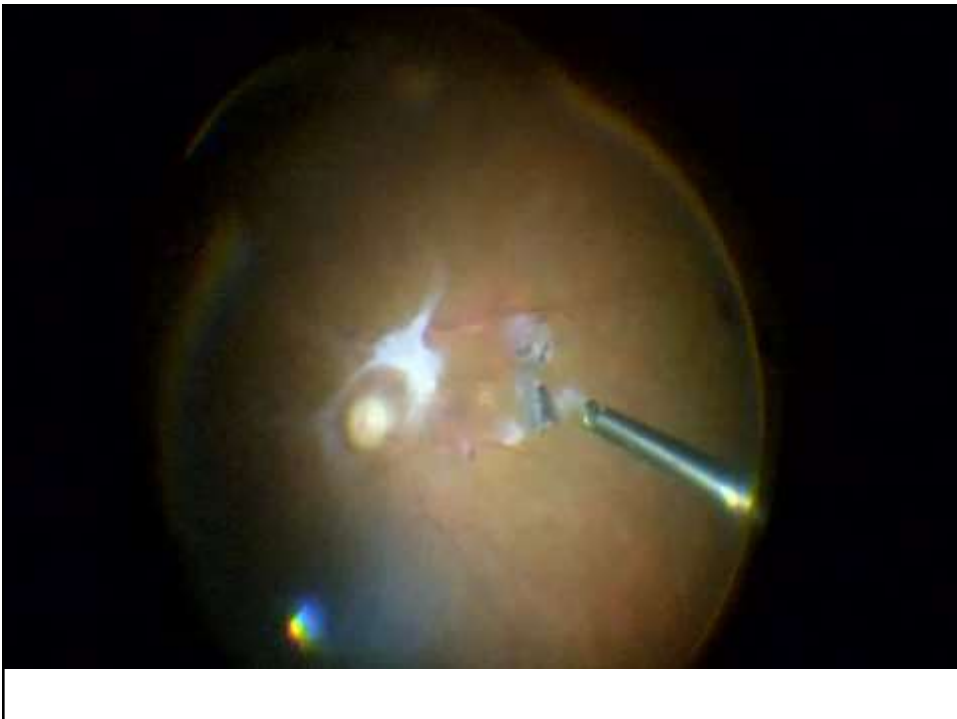
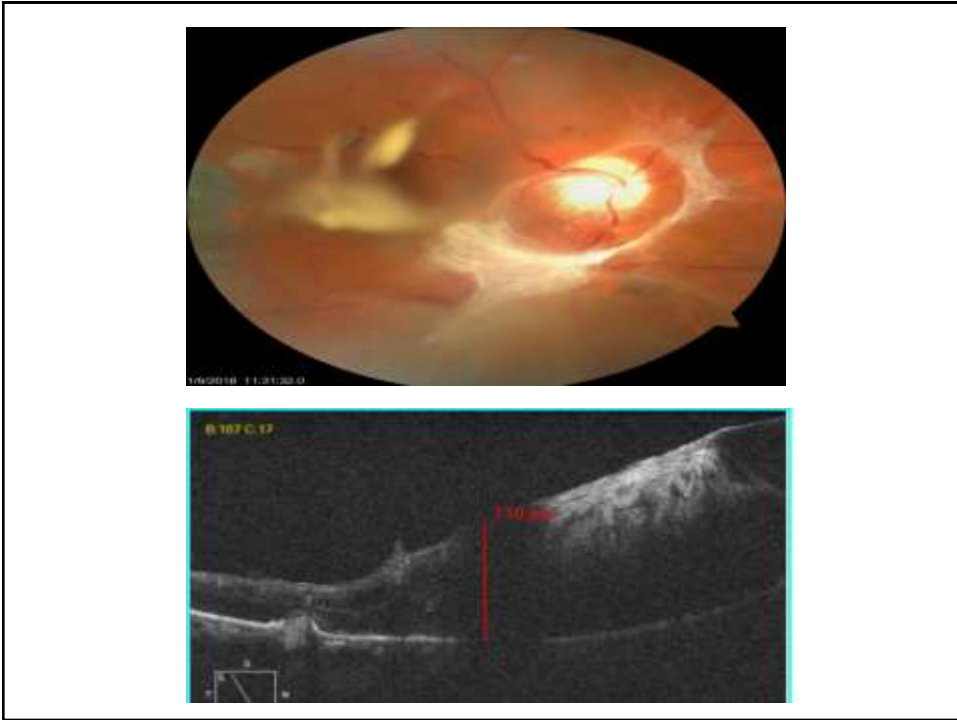BCVA : CF 1m | 0.1

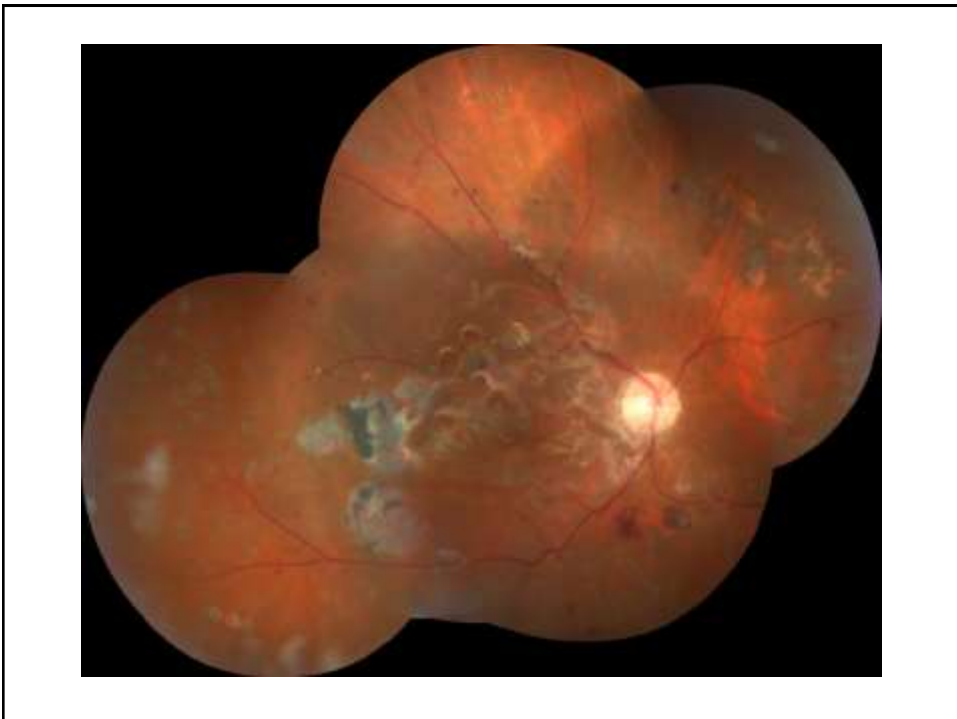
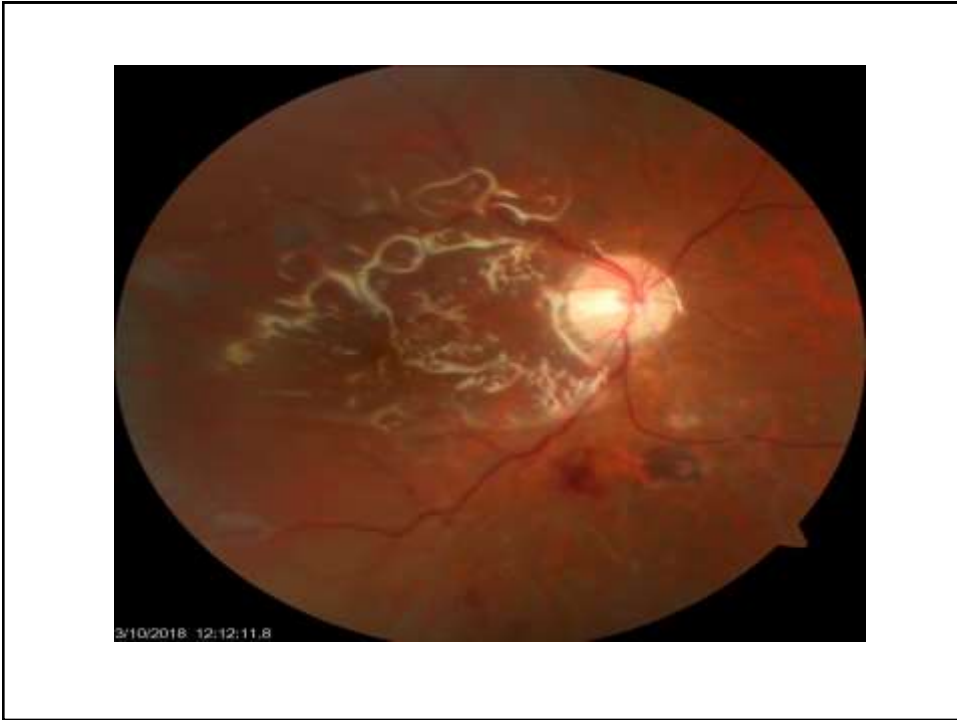Remarks : reading

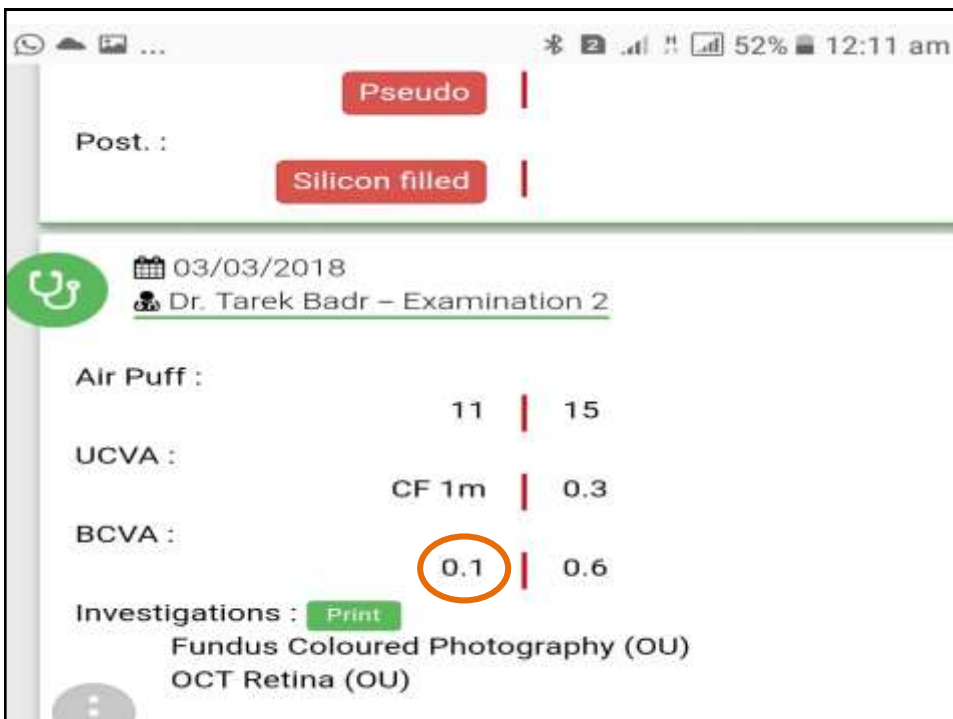
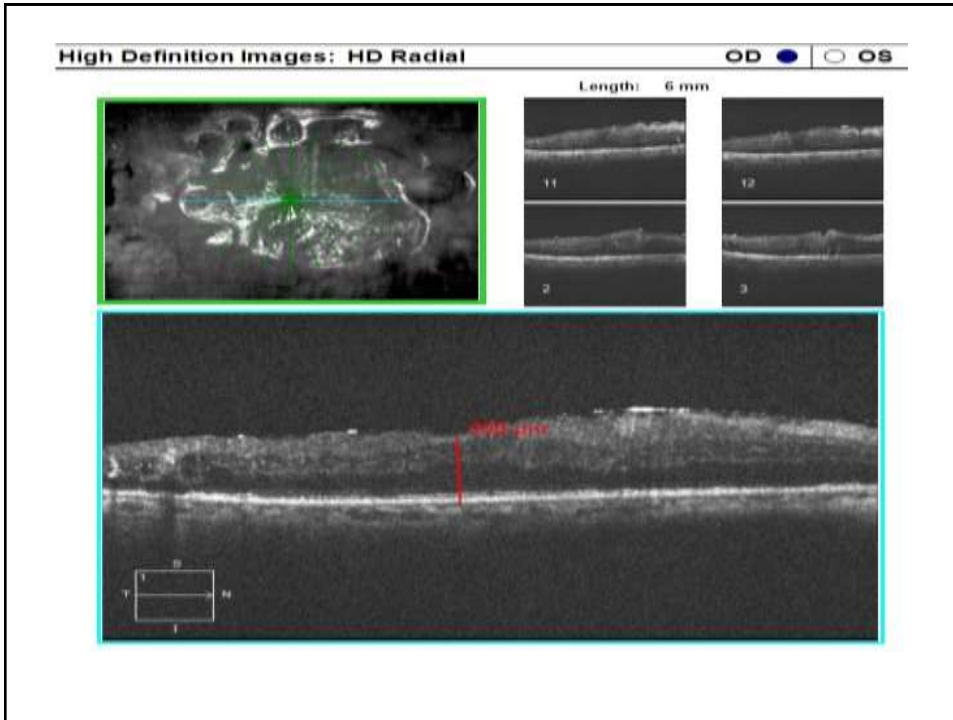
Lens : Pseudo | NC1 AC2

Post : Fibrovascular membrane involving macula | stable DR



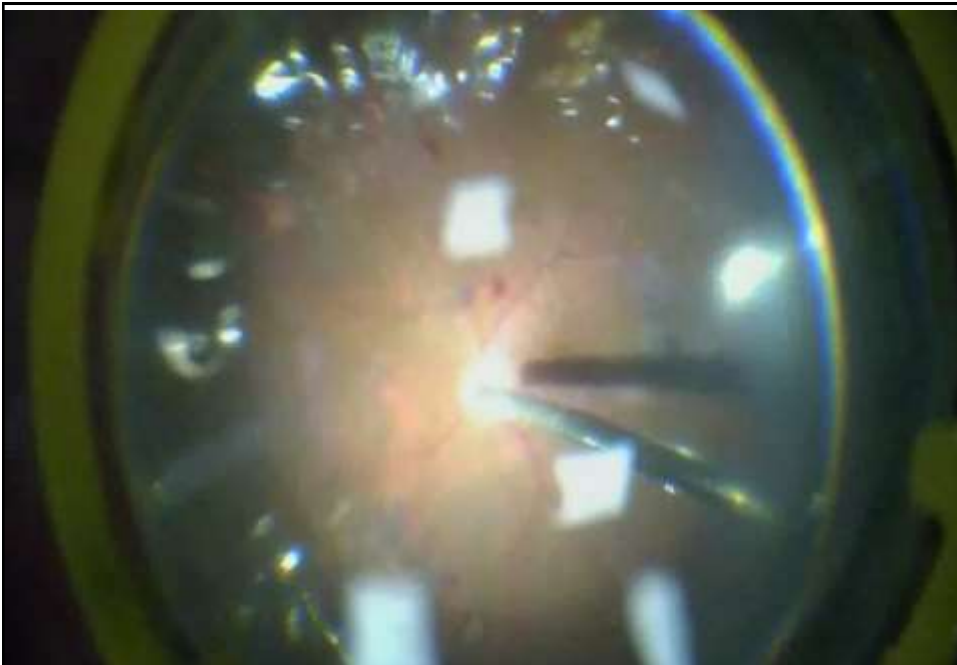


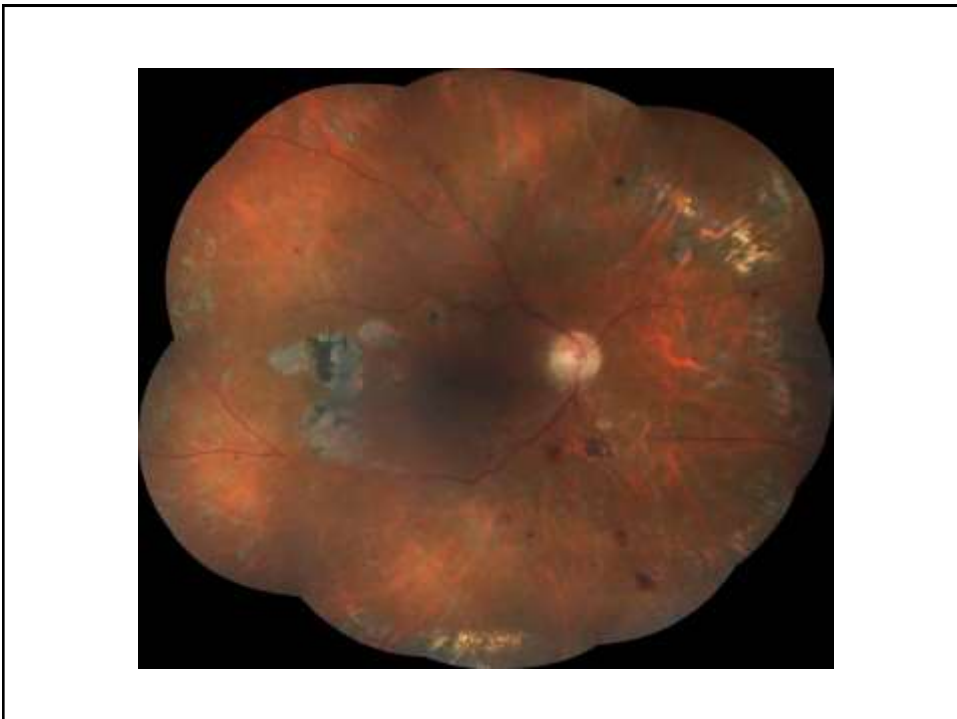
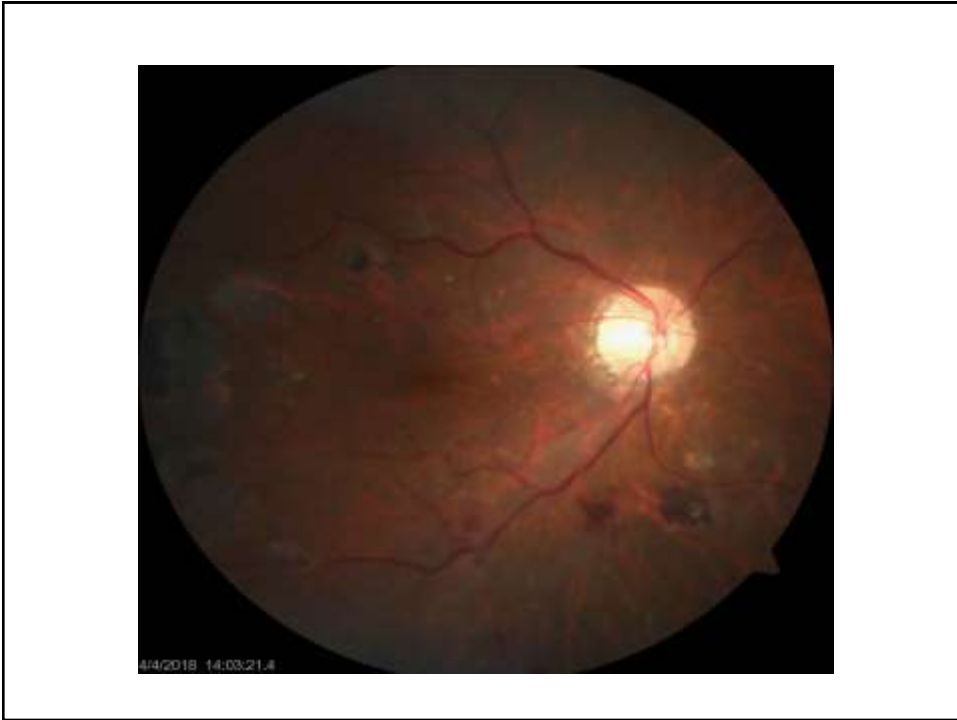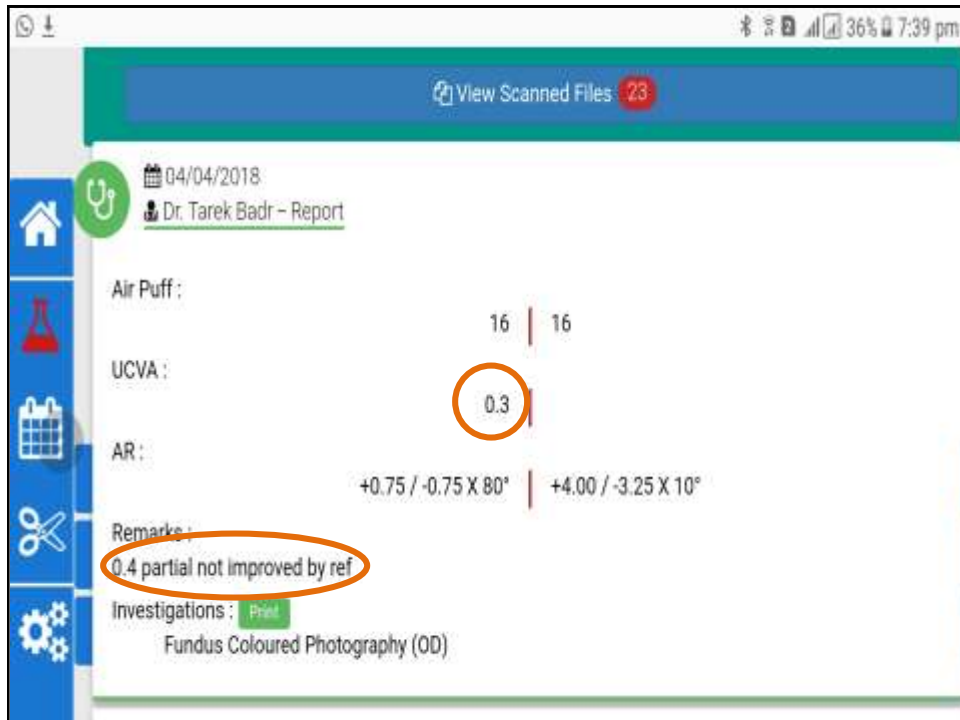


A Month later ,

Silicone removal done







Take Home Message

Anti-VEGF should be used cautiously or better to be avoided in cases with **fibrovascular membranes** when we are not planning to do vitrectomy.

THANK YOU